

ERRATUM

In *Journal of the International Academy of Periodontology*, Volume 13, Number 2, July 2011; in the article “Chronic Periodontitis with Multiple Risk Factor Syndrome: A Case Report” by Masayuki Shimoe, Tadashi Yamamoto, Yoshihiro Iwamoto, Nobuyuki Shiomi, Hiroshi Maeda, Fusanori Nishimura and Shogo Takashiba (*J Int Acad Periodontol* 2011; **13**(2): 40-47.)

An incorrect *Figure 5* on page 45 was inadvertently published. The corrected figure is provided below.

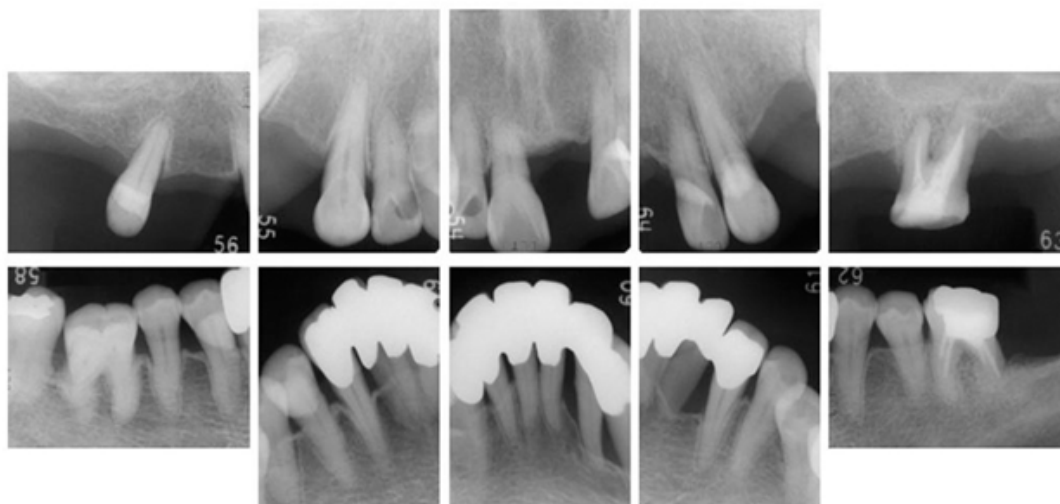


Figure 5. Dental radiographs during supportive periodontal therapy: Obvious crestal lamina dura was noted at the interproximal sites in the alveolar bone. No incipient bone loss was observed.