

Influence of Adrenergic Neuromodulation during Induction of Periodontitis in Rats

Luana Galvão Martins¹, Carolina Servidoni Spreafico¹, Poliana Giacomini Tanobe¹, Talita Angelina Aureliano Tavares¹, Myrella Lessio Castro², Gilson Cesar Nobre Franco³, Renata Falchete do Prado¹ and Ana Lia Anbinder¹

¹Department of Bioscience and Oral Diagnosis, Institute of Science and Technology, (ICT) UNESP - Univ Estadual Paulista, São José dos Campos, SP, Brazil

²Piracicaba Dental School, University of Campinas, Piracicaba, SP, Brazil; Ribeirão Preto Dental School, University of São Paulo, Ribeirão Preto, SP, Brazil.

³State University of Ponta Grossa – UEPG, General Biology, Telêmaco Borba, PR, Brazil

Abstract

The action of the sympathetic nervous system in the control of bone remodeling and immunoinflammatory responses is the basis of the hypothesis that its modulation can influence the progress of periodontal disease. The aim of this study was to analyze the effects of the blockade and of the activation of β -adrenergic receptors in periodontal disease in rats. Thirty-two rats were divided into four groups: 1) animals with induced periodontitis that received propranolol (a non-selective β -adrenergic antagonist) 0.1 mg/kg (PRO); 2) animals with induced periodontitis that received isoproterenol (a non-selective β -adrenergic agonist) 0.75 mg/kg (ISO); 3) animals with induced periodontitis and without drug treatment (L); and 4) animals without induced periodontitis and without drug treatment - control (C). After 14 days of treatment, the rats were euthanized. Right hemi-mandibles were removed and lingual alveolar bone loss measurements were made under a stereomicroscope. Left hemi-mandibles were decalcified and submitted to routine histological preparation for the evaluation of alveolar bone loss in furcation regions, amount of gingival collagen, and immunohistochemistry for receptor activator of nuclear factor-kappa B ligand (RANKL)/osteoprotegerin (OPG) ratio. Animals treated with isoproterenol had significantly more lingual alveolar bone loss than others. The percentage of collagen in gingiva was greater in the propranolol group than in the isoproterenol group. No statistical differences were found among groups with periodontal disease in any other evaluations. The activation of β -adrenergic receptors increased the lingual alveolar bone loss; however, in the model used, the use of β -adrenergic antagonist drugs was not able to modulate the host response significantly. Activation and inhibition of β -receptors have antagonistic actions in collagen degradation in animals with periodontal disease.

Keywords: *Propranolol, isoproterenol, periodontal diseases, sympathetic nervous system*

Introduction

Activation of the local immune and inflammatory responses in the host, combined with bacterial biofilm

production, is essential for the tissue destruction that occurs in periodontal disease. In fact, modulation of the host response has been studied as an adjunct to conventional periodontal therapy (Shinwari *et al.*, 2014).

Traditionally, the control of bone remodeling is related to many factors including nutritional status, humoral factors, and biomechanical stress. However, over the last two decades, the involvement of the autonomic nervous system in the control of bone remodeling has become evident (Ji-Ye *et al.*, 2013; Elefteriou *et al.*, 2014).

Correspondence to: Ana Lia Anbinder, Av Engenheiro Francisco José Longo, 777, São José dos Campos, São Paulo, CEP: 12.245-000, Brazil. Tel: +55-12-3947-9358; Fax: +55-12-3947-9010; E-mail: ana.anbinder@fosjc.unesp.br

Histological studies have shown that both the bone and the periosteum receive a rich supply of sensory and sympathetic nerve fibers (Chenu, 2004). In addition, nerve endings have been found in direct contact with bone cells, and catecholamine-containing axons have been identified near osteoblasts *in vivo* (Serre *et al.*, 1999).

Postganglionic neurons from the sympathetic nervous system release norepinephrine that activates adrenergic receptors ($\alpha 1$, $\alpha 2$, $\beta 1$ -AR, $\beta 2$ -AR, $\beta 3$ -AR) distributed in different tissues. $\beta 2$ -ARs are expressed by osteoblasts and osteoclasts (Motyl and Rosen, 2012; Kondo *et al.*, 2013). $\beta 2$ -AR-deficient mice have an increased number of osteoblasts and increased bone formation rates, which suggests that the autonomic nervous system inhibits osteoblast function (Karsenty and Eleftheriou, 2008). β -adrenergic signaling also directly stimulates osteoclastogenesis through $\beta 2$ -AR on osteoclasts via reactive oxygen species generation (Kondo *et al.*, 2013).

Although overall β -blocker use has been mainly associated with reduced fracture risk and increased bone mineral density (Eleftheriou *et al.*, 2014), pharmacological experiments have produced contradictory results, showing that β -blockers can improve (Bonnet *et al.*, 2006; Bonnet *et al.*, 2008a), do not influence (Marenzana *et al.*, 2007; Veldhuis-Vlug *et al.*, 2015), and can be detrimental for bone mass and microstructure (Bonnet *et al.*, 2008b), possibly due to sympathetic actions at different levels ranging from the central nervous system to the bone cells themselves (Reid, 2008). Similarly, while most authors have shown negative effects of β -adrenergic agonists in bone (Bonnet *et al.*, 2005a, 2005b; Kondo and Togari, 2011), some have demonstrated the prevention of bone loss (Zeman *et al.*, 1991). Especially in humans, there are several variables that are difficult to control and that may contribute to the different results found, such as patient number, drug exposure time, doses, adrenergic receptor (AR) selectivity, age of patients and methodologies (Eleftheriou *et al.*, 2014).

The sympathetic nervous system also controls the immune homeostasis under conditions of stress or immune activation through the release of noradrenaline and adrenaline from the adrenal medulla. These catecholamines interact with ARs expressed on immune cells (predominantly $\beta 2$, but also $\alpha 1$), subsequently activating signaling pathways that alter their cellular functions (Bellinger and Lorton, 2014). However, the action of the sympathetic nervous system during inflammation is not simple, since it can elicit pro- and anti-inflammatory responses depending on the context, activated cells and receptors. α - or β -ARs activation promotes lymphopoiesis, but suppresses *in vivo* granulocyte/monocyte production. In eosinophils, neutrophils, mast cells and basophils, natural-killer cells and macrophages/dendritic cells, $\beta 2$ -AR activation promotes mainly anti-

inflammatory actions, while $\alpha 1$ -AR activation is related, in most situations, to pro-inflammatory events (Bellinger and Lorton, 2014).

Emotional stress has been associated with increased severity of periodontal disease in susceptible individuals (Doyle and Bartold, 2012). Stress has also been shown to increase the mRNA levels of the pro-inflammatory cytokines interleukin (IL)-1 β , IL-6 and interferon (IFN)-gamma, the anti-inflammatory cytokine IL-10 and receptor activator of nuclear factor-kappa B ligand (RANKL) in areas with periodontal disease (Peruzzo *et al.*, 2008). Psychological stress increases IL-1 β in the gingival crevice in experimental gingivitis while acute stress stimulates an increase of IL-8 in patients with gingivitis. Local pro-inflammatory cytokines induced by stress may directly regulate periodontitis (Weik *et al.*, 2008).

According to reports showing that the sympathetic nervous system is involved in the control of bone remodeling and immunoinflammatory responses, this study sought to assess the action of the sympathetic nervous system in the pathogenesis of periodontal disease by evaluating the effects of blockade (by using propranolol, a non-selective β -antagonist) and activation of β -ARs (by using isoproterenol, a non-selective β -agonist) in a model of induced periodontitis.

Materials and methods

Thirty-two male Wistar rats (90 days old) were kept in cages at room temperature and they were allowed food and water *ad libitum*. This project was approved by the ethics committee at our institution (protocol #6/2010) and all procedures were performed in a manner to minimize animal suffering.

The animals were divided into four groups (8 animals/group): 1) the propranolol group (PRO), animals with induced periodontitis that received propranolol (Sigma-Aldrich, St Louis, MO, US) at 0.1 mg/kg/day (Bonnet *et al.*, 2006); 2) the isoproterenol group (ISO), animals with induced periodontitis that received isoproterenol (Sigma-Aldrich) at 0.75 mg/kg/day; (3) the ligature group (L), animals with induced periodontitis that received saline solution; and (4) control group (C), animals without induction of periodontitis, but which underwent manipulation in the same manner as the other groups and received subcutaneous injections of saline.

To induce periodontitis, the animals were first anesthetized intramuscularly with xylazine (13 mg/kg; Anasedan, Vetbrands, Paulínia, SP, Brazil) and ketamine (33 mg/kg; Dopalen, Vetbrands), and ligature was performed with 2 threads of 4-0 black silk (Ethicon - Johnson & Johnson, São José dos Campos, SP, Brazil) around the mandibular first molars. The loops at the ends of the silk ligature remained on the mesial surface of the tooth.

The treatments, which were administered by subcutaneous injection, began the day after insertion of the ligature.

Fifteen days after the insertion of the ligatures, the rats were euthanized with an overdose of anesthetics; this period was previously demonstrated to be effective in the development of experimental periodontal disease (Branco-de-Almeida *et al.*, 2012). The jaws were removed and fixed in formalin.

Macroscopic analysis of lingual alveolar bone loss

The right hemi-mandibles were macerated in 2 N sodium hydroxide, stained with 1% methylene blue, and the lingual surface (Anbinder *et al.*, 2016) was photographed under a stereomicroscope (25X magnification). The alveolar bone loss on the lingual side was expected to be greater in comparison to the buccal side in the region of the mandibular molar (Sato *et al.*, 2005; Macri *et al.*, 2014). Linear measurements between the cemento-enamel junction and the alveolar bone crest, at the midpoint of the mesial, median and distal roots of the first molar, were evaluated using the Image J software version 1.43u (National Institutes of Health, Bethesda, MD, US, Figure 1A). The mean of three measurements was used for statistical analysis. One single examiner performed blind analysis.

Histological analysis

The left hemi-mandibles were decalcified in a 10% aqueous solution of ethylenedinitrilotetraacetic acid for 90 days. Serial sections, obtained in the mesiodistal direction, were stained with hematoxylin and eosin (HE), picosirius red for collagen detection, or were evaluated immunohistochemically for RANKL and osteoprotegerin (OPG) expression. Then bone loss in the furcation area, the percentage of gingival collagen and the RANKL/OPG ratio were calculated.

Alveolar bone loss in the furcation region

Five semi-serial sections stained with HE were photographed at an original magnification of 50X. The area of alveolar bone loss in the furcation region was defined as that not occupied by bone tissue between the interradicular septum and the cementum in the furcation (Figure 1B). Measurements were obtained using the Image J software.

Percentage of gingival collagen

Three sections stained with picosirius red were scanned in the region of connective tissue above the mesial bone crest using polarization microscopy at 400X magnification (Figure 1C). The collagenous area was obtained using Image J and Adobe Photoshop software (version 7.0.1, Adobe Systems Incorporated, San Jose, CA, US). To determine the percentage of gingival collagen area (presenting reddish fibers), the scanned images were opened in Adobe Photoshop software and the “color

range” selection tool was used to select all reddish fibers. The image was then copied and pasted to a newly created file and saved. Next, the Image J program was used to binarize the image and the percentage area of the collagen was calculated (Figure 1D).

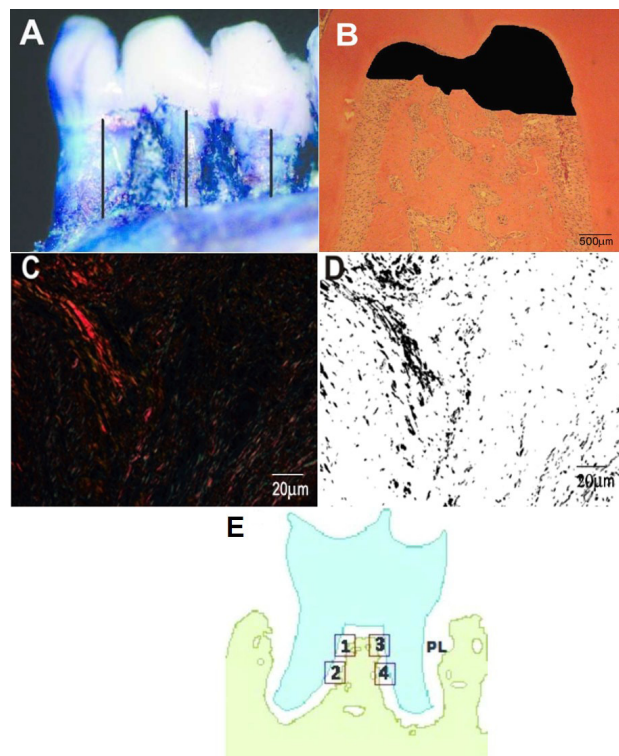


Figure 1. An overview of the methodology used. A) Macroscopic image obtained using stereomicroscopy with linear measurements of bone loss in the roots of the first molar. **B)** Microscopic image showing the area of alveolar bone loss in the furcation region. HE staining. Original magnification: 50X. **C)** Collagenous area presenting reddish fibers above mesial crest. Picosirius staining under polarized microscope. Original magnification: 400X. **D)** Binarized image, obtained in Image J software, after selection of reddish fibers in Figure 1C. Original magnification: 400X. **E)** Schematic representation of photographed areas for counting immunolabeled cells in the furcation region with alveolar bone. PL, periodontal ligament.

Immunohistochemistry

Sections 4 µm in thickness were labeled using anti-RANKL ([sc-7628] Santa Cruz Biotechnology, Santa Cruz, CA, US) and anti-OPG ([ab-73400] Abcam, Cambridge, UK) antibodies. After deparaffinization and rehydration, antigen retrieval was performed with pepsin pH 1.8 in an incubator (1 h), followed by blockade of endogenous peroxidase activity in methanol and 6% H₂O₂ (10 min). The sections were incubated with bovine serum albumin/Tris (1 h), followed by incubation with anti-RANKL (1:100 dilution) and anti-OPG (1:500 dilution) antibodies at room temperature (2 h).

The microscope slides were then incubated with biotinylated secondary antibodies (LSAB kit, Dako, Carpinteria, CA, US) at room temperature for 1 h. Labeling was performed using diaminobenzidine (Dako, Carpinteria, CA, US), and the sections were counterstained with hematoxylin. Positive controls were performed using peripheral giant cell lesions, and negative controls were performed by replacing the primary antibodies with phosphate buffered saline (PBS). Four histological fields were photographed in the furcation region under 400X magnification in order to count the immunolabeled cells that lined the alveolar bone (Figure 1E) using Image J software. The mean number of positive cells in contact with the bone in all four histological fields was calculated, and the ratio between RANKL-positive and OPG-positive cells was determined for each animal.

Statistical analysis

Normality was assessed by using the Kolmogorov-Smirnov test. Data from the L and C groups obtained after macroscopic analysis of lingual alveolar bone loss and histological alveolar bone loss in the furcation region were submitted to Student's *t*-test in order to confirm periodontitis induction. One-way analysis of variance (ANOVA with the *post hoc* Tukey test) was used to compare groups L, PRO and ISO in all analyses. A significance level of 5% was adopted.

Results

Due to technical difficulties, an animal in group L was excluded from the analysis of bone loss in the furcation region and the percentage of gingival collagen. In addition, an animal in the ISO group was excluded from the immunohistochemical analysis.

Macroscopic analysis

After Student's *t*-test, a statistically significant difference was found between groups C and L ($t = 12.78$,

$p < 0.001$, Figure 2A). Although in animals without periodontitis the bone level was situated apical to the cemento-enamel junction, the insertion of the ligature successfully induced alveolar bone loss.

Comparing only groups with periodontitis, aiming to evaluate the drug effect on bone loss during periodontitis, a statistically significant difference was found among the groups (ANOVA $F [2.21] = 14.824$; $p = 0.001$), with greater loss observed in the ISO group (Figure 2B).

Alveolar bone loss in the furcation region

Significantly greater furcation bone loss was found in animals with induced periodontitis, in comparison to controls, after Student's *t*-test ($t = 5.64$, $p < 0.001$, Figure 3A), confirming, once again, the effectiveness of the periodontal disease induction model.

Among groups with induced periodontitis, drugs did not significantly influence furcation bone loss, as the furcation bone loss data analysis showed no differences among groups (ANOVA $F [2.20] = 0.520$; $p = 0.603$; Figure 3B). However, numerically, greater values were found in the ISO group.

Immunohistochemistry

RANKL and OPG were expressed by mesenchymal cells, especially osteoblasts and ligament fibroblasts (Figures 4A, 4B and C). However, only cells lining the bone surface were counted (Figure 4C). Aiming to demonstrate a tendency of resorptive phenomena through RANKL/OPG ratio, inferential statistical analysis was performed. The analysis demonstrated no effects of drugs on these bone markers. The ratio of immunolabeled cells expressing RANKL and OPG (ANOVA $F [2.20] = 1.622$; $p = 0.223$; Figure 4D) was similar in all groups.

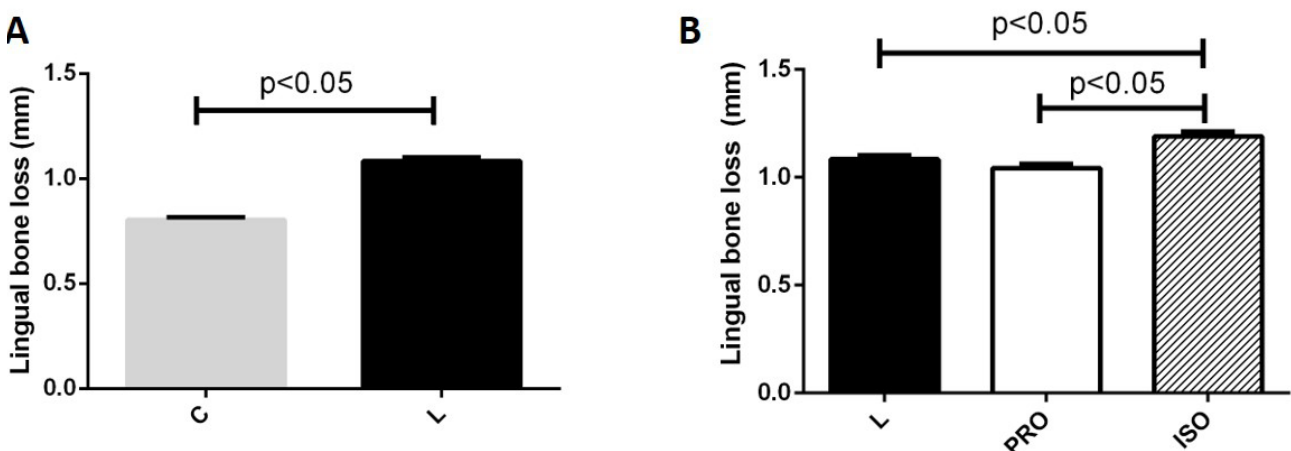


Figure 2. Macroscopic analysis of the lingual alveolar bone loss. A) Means and standard errors of values of lingual alveolar bone loss after the comparison between groups with no drug treatment, with (L) and without (C) periodontal disease induction. There was a statistically significant difference (Student's *t*-test, $p < 0.05$) between them, confirming the effectiveness of the periodontal disease induction model. B) Means and standard errors of values of lingual alveolar bone loss after the comparison among groups with induced periodontal disease, showing greater bone loss in ISO group (ANOVA followed by Tukey test, $p < 0.05$). C, control group; L, ligature group; PRO, propranolol group; ISO, isoproterenol group.

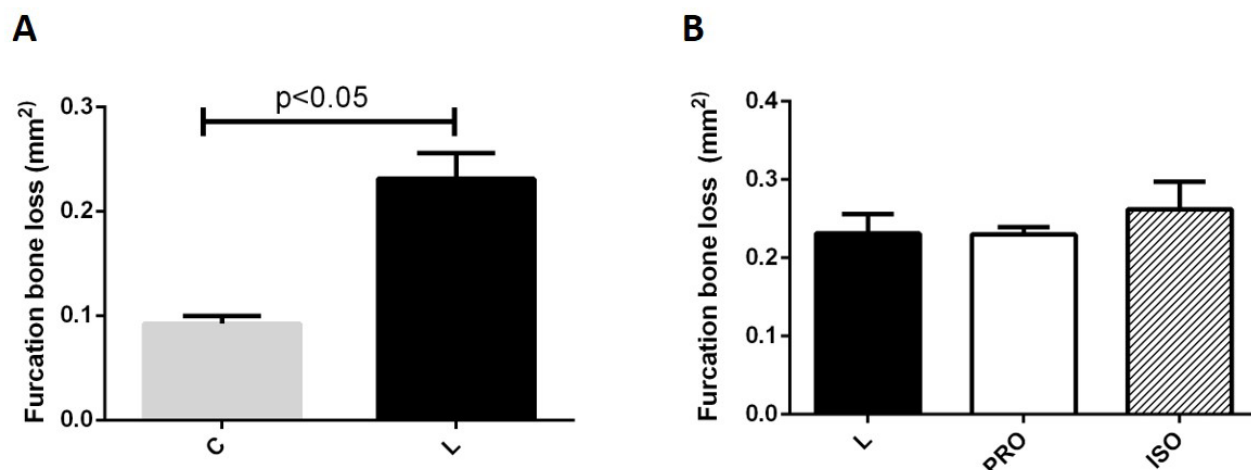


Figure 3. Alveolar bone loss in the furcation region. A) Means and standard errors of values of alveolar bone loss in the furcation region after the comparison between groups with no drug treatment, with (L) and without (C) periodontal disease induction. There was a statistically significant difference between them, confirming the effectiveness of the periodontal disease induction model (Student's *t*-test, $p < 0.05$). B) Means and standard errors of values of alveolar bone loss in the furcation region after the comparison among groups with induced periodontal disease showing no differences among them (ANOVA followed by Tukey test, $p < 0.05$). C, control group; L, ligature group; PRO, propranolol group; ISO, isoproterenol group.

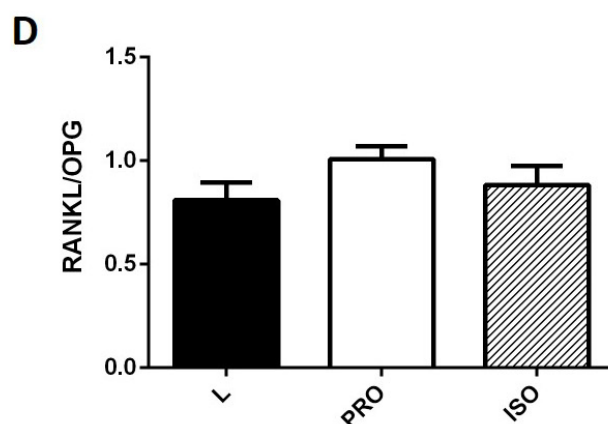
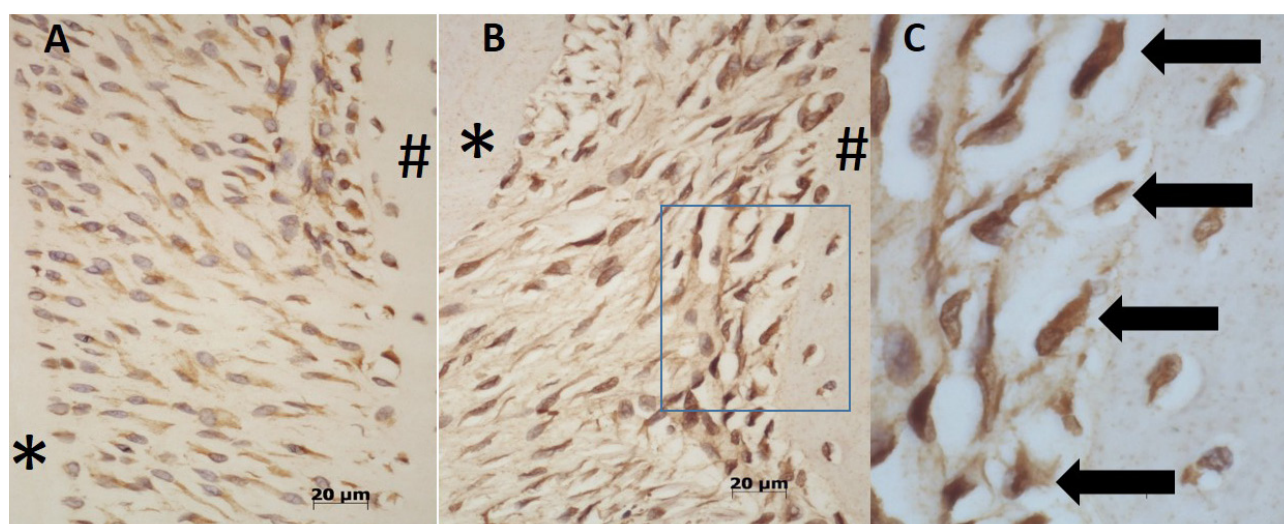


Figure 4. Immunohistochemistry. A) Osteoprotegerin (OPG) immunolabeled cells (cytoplasmic staining). Original magnification 400X. B) Receptor activator of nuclear factor kappa-B ligand (RANKL) immunolabeled cells (cytoplasmic staining). Original magnification 400X. Marked area is shown at higher magnification in C. C) Higher magnification of marked area in B, to show that only positive cells that lined the bone were counted (arrows). *Dentin; #bone. D) Means and standard errors of the values of the ratio of immunolabeled cells RANKL/OPG among groups. There were no statistical differences among groups (ANOVA followed by Tukey test, $p < 0.05$). L, ligature group; PRO, propranolol group; ISO, isoproterenol group.

Percentage of gingival collagen

Analysis of the percentage of gingival collagen showed a difference between treatments with propranolol and isoproterenol (ANOVA $F [2,20] = 4.683; p = 0.022$), with propranolol treatment resulting in a greater collagen area compared to the treatment with isoproterenol (Figure 5).

Discussion

Recent studies have provided evidence that the sympathetic nervous system is involved in the control of bone metabolism by modulating the resorption and activity of bone cells (Ji-Ye *et al.*, 2013; Elefteriou *et al.*, 2014). In the present study, propranolol was used as a non-selective blocker of β -adrenergic receptors to evaluate the role of the sympathetic nervous system in the pathogenesis of periodontal disease, and we found no significant difference in alveolar bone loss following administration of this drug compared to animals with induced periodontitis that received saline solution. In contrast, Rodrigues *et al.* (2012) detected a reduction in bone loss in experimental periodontitis in rats following the use of

propranolol (0.1 mg/kg/day) for 30 days, while Okada *et al.* (2010) also found a reduction in bone loss in periodontitis following the use of propranolol (1 mg/kg/day) for 22 days. We choose the dose of 0.1mg/kg/day based on previous studies that showed this dose was sufficient to reduce bone resorption in the femur, tibia and vertebrae of rats after 10 weeks of treatment (Bonnet *et al.* 2006; Bonnet *et al.*, 2008a).

Moreover, Folwarczna *et al.* (2011) investigated the effects of propranolol on the skeletons of rats with prednisolone-induced osteopenia, and the authors observed deleterious effects of drug treatment on the bone tissue, which contributes to explaining the antagonistic results that have often been reported in human studies. In particular, some of these previous studies reported a positive association between the use of β -blockers and bone mineral density and the risk of fractures (Schlienger *et al.*, 2004), while others reported no effect of the drug or deleterious effects to the bone (Rejnmark *et al.*, 2004; de Vries *et al.*, 2007). The study by Folwarczna *et al.* (2011) further suggested that adrenergic receptor antagonists may exert biphasic effects, both favorable and deleterious to the skeleton, depending on dose and individual susceptibility.

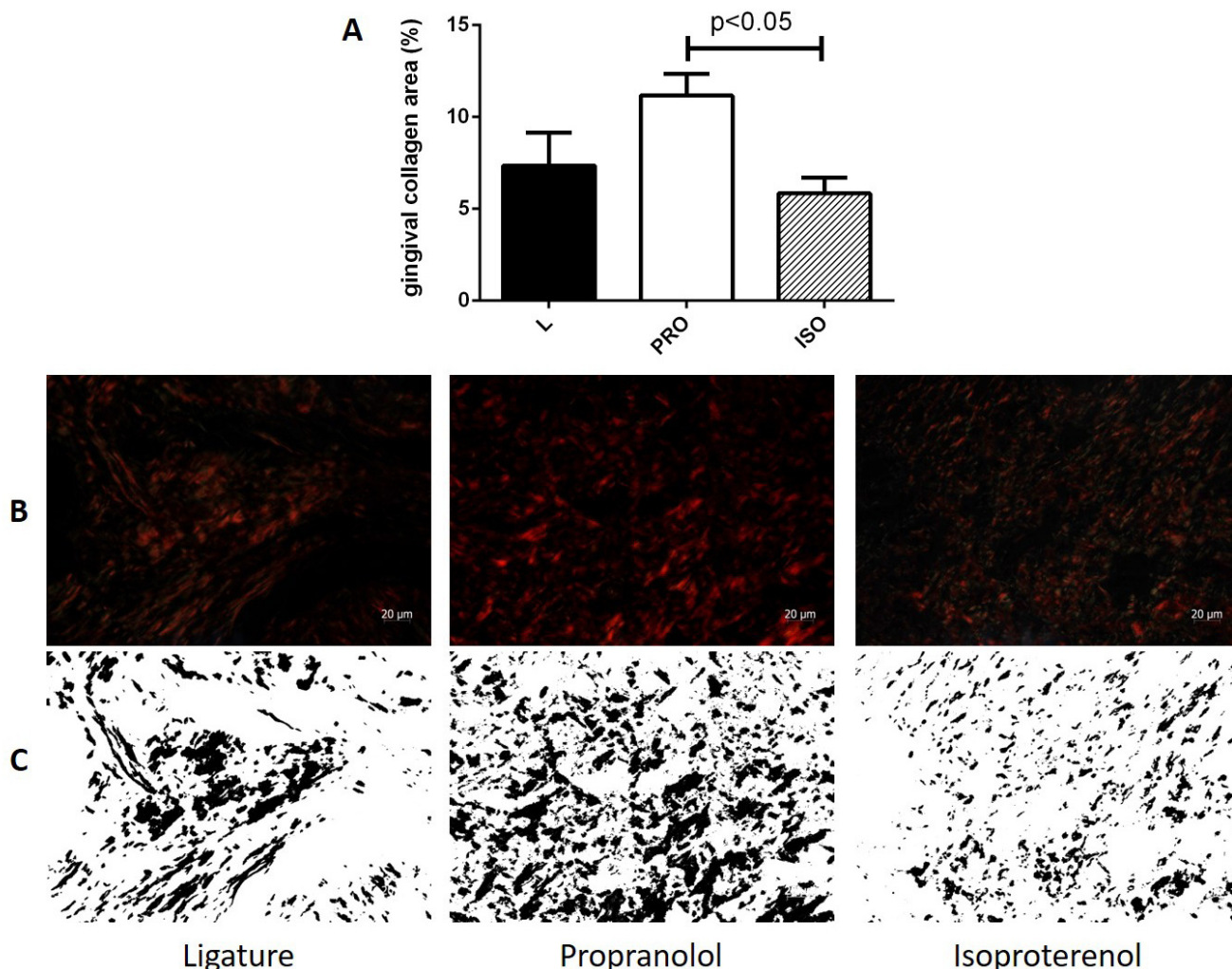


Figure 5. A) Percentage of gingival collagen. Means and standard errors of the values of percentage of gingival collagen, showing difference between PRO and ISO groups (ANOVA followed by Tukey test, $p < 0.05$). B) Photomicrographs of the region of connective tissue above the mesial bone crest using polarization microscopy (at 400X magnification) of a representative animal from each group. C) Same images from B, binarized with the aid of Image J software. The difference between black area (gingival collagen) in the PRO and ISO groups can be noted. L, ligature group; PRO, propranolol group; ISO, isoproterenol group.

Based on previous data in the literature that demonstrated that mice lacking $\beta 2$ -AR have a high bone mass phenotype (Elefteriou *et al.*, 2005) and animals with double deletion phenotype (lacking $\beta 1$ - and $\beta 2$ ARs) have reduced bone mass (Pierroz *et al.*, 2005), it is suggested that high doses of propranolol may mimic the deletion of $\beta 1$ - and $\beta 2$ ARs, explaining the better effects of low doses of the β -antagonist (Bonnet *et al.*, 2008b; Rodrigues *et al.*, 2012).

The animals that received propranolol showed a greater percentage of gingival collagen area compared to those treated with isoproterenol. These findings highlight, again, the influence of the sympathetic nervous system in periodontitis, with the tested drugs showing antagonistic effects on collagen degradation but without producing a significant difference compared to the control treatment. The influence of the sympathetic nervous system in periodontium wound healing was studied by other authors, who found an increase in fibroblast proliferation after sympathetic ganglionectomy (Wucherpfennig *et al.*, 1990). Higher norepinephrine levels were associated with higher levels of matrix metalloproteinase (MMP)-2 in patients with blister wounds created in skin after UV-B irradiation (Yang *et al.*, 2002) supporting the effect of stress and the sympathetic nervous system on collagen remodeling. Although the amount of collagen in groups ISO and PRO was not significantly different from the control, which is not clinically significant, the antagonistic effect of the drugs indicates one more action of the sympathetic nervous system.

Although propranolol was not found to influence lingual or furcation bone loss during periodontitis in our study, this was not the case for isoproterenol, which caused greater lingual alveolar bone loss in comparison to the PRO and L groups. The route and dose of isoproterenol administration were, initially, based on Issy *et al.* (2009) who used 2 mg/kg/day of isoproterenol in rats. However, in our hands, this dose induced a high mortality rate. We reduced the dose in a pilot study to 0.75 mg/kg/day, which was enough to reduce the mortality rate and to produce the expected results of a β -adrenergic agonist on heart and salivary gland weight (data not shown). The effect of isoproterenol on lingual alveolar bone loss confirms the influence of the sympathetic nervous system on periodontal disease and is consistent with those of previous studies, which observed greater bone loss and increased osteoclast activity following the use of β -adrenergic agonists (Bonnet *et al.*, 2005a; 2005b; Kondo and Togari, 2011). Besides the association with osteoclastic activity, isoproterenol was recently proven to impair osteoblastic migration in association with suppression of cell cycle transition, opposite actions when compared to parathyroid hormone, in osteoblasts (Katsumura *et al.*, 2016).

Although there was greater lingual alveolar bone loss, no differences were found between the groups with

respect to bone loss in furcation area and RANKL/OPG immunostaining, which may be explained by the involvement of this region in the later stages of the disease. We used an observation period coincident with the peak of ligature-induced periodontitis in rats, as reported in the literature (Kuhr *et al.*, 2004).

The activation of sympathetic nerves is typical in chronic stress or depression. Many experimental and clinical studies have showed the negative impact of physiological stress in periodontal disease due to the down-regulation of the immune response (Genco *et al.*, 1998). Physiological responses to stress modulate the immune system through endocrine and neural systems in some pathways: the release of adrenaline and nor-adrenaline from the adrenal medulla after the activation of the sympathetic nervous system, the release of glucocorticoid hormones from the adrenal cortex promoted by hypothalamus-pituitary-adrenal axis, and the release of neuropeptides from sensory nerve fibers (Genco *et al.*, 1998). Besides this down-regulation of the immune system, stress can mediate risk for periodontitis through changes in life-style such as smoking, fat- and sugar-rich diets, and poor hygiene habits (Genco *et al.*, 1998).

The mechanisms by which psychological stress may modify the release of local cytokines are unknown so far. Many preformed cytokines are found stored within the granules of various cells, which may be released very quickly under stress, probably through neuropeptidergic activation (Weik *et al.*, 2008).

Although psychological stress and administration of a β -agonist can both activate the sympathetic nervous system, the mechanism of action and activated pathways may differ. Goebel *et al.* (2000) evaluated the effects of psychological stress, exercise and infused isoproterenol on lipopolysaccharide-induced *in vitro* production of IL-6 and tumor necrosis factor (TNF)- α and found increased levels of cytokines after psychological stress and exercise, but lower levels of TNF- α and no change in IL-6 after isoproterenol infusion. Their results showed evidence of an anti-inflammatory effect of β -AR activation.

Despite the reported anti-inflammatory action of isoproterenol (Goebel *et al.*, 2000), after using this drug we found an increase in lingual alveolar bone resorption due to periodontitis. To the best of our knowledge, no previous report has been published about the effect of β -AR activation during periodontitis. Considering the actions of the sympathetic nervous system activation in bone and in inflammation in periodontal disease, which is characterized by inflammation and bone resorption, we can conclude that (besides the reported anti-inflammatory action) isoproterenol aggravated periodontitis and bone resorption. So, one more hypothesis by which sympathetic nervous system activation affects periodontal disease could be raised: the direct effect of β -AR activation on bone resorption.

In summary, our results suggest that the activation of β -ARs stimulated lingual alveolar bone loss and that the activation and inhibition of β -AR have antagonistic actions in collagen degradation in animals with periodontal disease.

Acknowledgments

This study was supported by Univ Estadual Paulista-UNESP, São Paulo Research Foundation- FAPESP (grant #2011/06115-9) and the National Council for Scientific and Technological Development - CNPq provided scientific initiation scholarships to CSS and TAT, respectively.

References

- Anbinder AL, Moraes RM, Lima GM, *et al.* Periodontal disease exacerbates systemic ovariectomy-induced bone loss in mice. *Bone* 2016; **83**:241-247.
- Bellinger DL and Lorton D. Autonomic regulation of cellular function. *Autonomic Neuroscience: Basic and Clinical* 2014; **182**:15-41.
- Bonnet N, Benhamou C, Brunet-Imbault B, *et al.* Severe bone alterations under beta2 agonist treatments: bone mass, microarchitecture and strength analyses in female rats. *Bone* 2005a; **37**:622-633.
- Bonnet N, Benhamou C, Malaval L, *et al.* Low dose beta-blocker prevents ovariectomy-induced bone loss in rats without affecting heart functions. *Journal of Cellular Physiology* 2008a; **217**:819-827.
- Bonnet N, Brunet-Imbault B, Arletaz A, *et al.* Alteration of trabecular bone under chronic beta2 agonists treatment. *Medicine Science in Sports and Exercise* 2005b; **37**:1493-1501.
- Bonnet N, Laroche N, Vico L, Dolleans E, Benhamou C and Courteix D. Dose effects of propranolol on cancellous and cortical bone in ovariectomized adult rats. *Journal of Pharmacology and Experimental Therapeutics* 2006; **318**:1118-1127.
- Bonnet N, Pierroz D and Ferrari S. Adrenergic control of bone remodeling and its implications for the treatment of osteoporosis. *Journal of Musculoskeletal and Neuronal Interactions* 2008b; **8**:94-104.
- Branco-de-Almeida LS, Franco GC, Castro ML, *et al.* Fluoxetine inhibits inflammatory response and bone loss in a rat model of ligature-induced periodontitis. *Journal of Periodontology* 2012; **83**:664-671.
- Chenu C. Role of innervation in the control of bone remodeling. *Journal of Musculoskeletal Neuronal Interactions* 2004; **4**:132-134.
- de Vries F, Souverein P, Cooper C, Leufkens H and van Staa T. Use of beta-blockers and the risk of hip/femur fracture in the United Kingdom and The Netherlands. *Calcified Tissue International* 2007; **80**:69-75.
- Doyle CJ and Bartold PM. How does stress influence periodontitis? *Journal of the International Academy of Periodontology* 2012; **14**:42-49.
- Elefteriou F, Ahn JD, Takeda S, *et al.* Leptin regulation of bone resorption by the sympathetic nervous system and CART. *Nature* 2005; **434**:514-520.
- Elefteriou F, Campbell P and Ma Y. Control of bone remodeling by the peripheral sympathetic nervous system. *Calcified Tissue International* 2014; **94**:140-151.
- Folwarczna J, Pytlik M, Sliwiński L, Cegiela U, Nowińska B and Rajda M. Effects of propranolol on the development of glucocorticoid-induced osteoporosis in male rats. *Pharmacology Reports* 2011; **63**:1040-1049.
- Genco RJ, Ho AW, Kopman J, Grossi SG, Dunford RG and Tedesco LA. Models to evaluate the role of stress in periodontal disease. *Annals of Periodontology* 1998; **3**:288-302.
- Goebel MU, Mills PJ, Irwin MR and Ziegler MG. Interleukin-6 and tumor necrosis factor- α production after acute psychological stress, exercise, and infused isoproterenol: Differential effects and pathways. *Psychosomatic Medicine* 2000; **62**:591-598.
- Issy AC, da Silva CA, Guimaraes FS and Del Bel EA. Different role of isoproterenol and NOS inhibitors on salivary ducts of rats. *Micron* 2009; **40**:343-349.
- Ji-Ye H, Xin-Feng Z and Lei-Sheng J. Autonomic control of bone formation: Its clinical relevance. *Handbook of Clinical Neurology* 2013; **117**:161-171.
- Karsenty G and Elefteriou E. Neuronal Regulation of Bone Remodeling. In Rosen CJ. (Ed). *Primer on the Metabolic Bone Diseases and Disorders of Mineral Metabolism*. Washington. The American Society for Bone and Mineral Metabolism, 2008.
- Katsumura S, Ezura Y, Izu Y, *et al.* Beta adrenergic receptor stimulation suppresses cell migration in association with cell cycle transition in osteoblasts-live imaging analyses based on FUCCI system. *Journal of Cellular Physiology*. 2016; **231**:496-504.
- Kondo H, Takeuchi S and Togari A. β -Adrenergic signaling stimulates osteoclastogenesis via reactive oxygen species. *American Journal of Physiology - Endocrinology and Metabolism* 2013; **304**:E507-515.
- Kondo H and Togari A. Continuous treatment with a low-dose β -agonist reduces bone mass by increasing bone resorption without suppressing bone formation. *Calcified Tissue International* 2011; **88**:23-32.
- Kuhr A, Popa-Wagner A, Schmoll H, Schwahn C and Kocher T. Observations on experimental marginal periodontitis in rats. *Journal of Periodontal Research* 2004; **39**:101-106.
- Lu H, Xu M, Wang F, Liu S, Gu J and Lin S. Chronic stress enhances progression of periodontitis via alpha1-adrenergic signaling: A potential target for periodontal disease therapy. *Experimental and Molecular Medicine* 2014; **46**:e118.
- Macri E, Lifshitz F, Ramos C, *et al.* Atherogenic cholesterol-rich diet and periodontal disease. *Archives of Oral Biology* 2014; **59**:679-686.

- Marenzana M, De Souza R and Chenu C. Blockade of beta-adrenergic signaling does not influence the bone mechano-adaptive response in mice. *Bone* 2007; **41**:206-215.
- Motyl KJ and Rosen CJ. The skeleton and the sympathetic nervous system: It's about time! *The Journal of Clinical Endocrinology and Metabolism* 2012; **97**:3908-3911.
- Okada Y, Hamada N, Kim Y, *et al.* Blockade of sympathetic beta-receptors inhibits *Porphyromonas gingivalis*-induced alveolar bone loss in an experimental rat periodontitis model. *Archives of Oral Biology* 2010; **55**:502-508.
- Peruzzo D, Benatti B, Antunes I, *et al.* Chronic stress may modulate periodontal disease: a study in rats. *Journal of Periodontology* 2008; **79**:697-704.
- Pierroz DD, Boussein M, Muzzin P, Rizzoli R and Ferrari SL. Bone loss following ovariectomy is maintained in absence of adrenergic receptor $\beta 1$ and $\beta 2$ signaling. *Journal of Mineral Research* 2005; **20**:S277.
- Reid I. Effects of beta-blockers on fracture risk. *Journal of Musculoskeletal Neuronal Interactions* 2008; **8**:105-110.
- Rejnmark L, Vestergaard P, Kassem M, *et al.* Fracture risk in perimenopausal women treated with beta-blockers. *Calcified Tissue International* 2004; **75**:365-372.
- Rodrigues WF, Madeira MF, da Silva TA, *et al.* Low dose of propranolol down-modulates bone resorption by inhibiting inflammation and osteoclast differentiation. *British Journal of Pharmacology* 2012; **165**:2140-2151.
- Sato H, Kawamura A, Yamaguchi M and Kasai K. Relationship between masticatory function and internal structure of the mandible based on computed tomography findings. *American Journal of Orthodontics and Dentofacial Orthopedics* 2005; **128**:766-773.
- Schlienger R, Kraenzlin M, Jick S and Meier C. Use of beta-blockers and risk of fractures. *Journal of American Medical Association* 2004; **292**:1326-1332.
- Serre C, Farlay D, Delmas P and Chenu C. Evidence for a dense and intimate innervation of the bone tissue, including glutamate-containing fibers. *Bone* 1999; **25**:623-629.
- Shinwari MS, Tanwir F, Hyder PR and Bin Saeed MH. Host modulation therapeutics in periodontics: Role as an adjunctive periodontal therapy. *Journal of the College of Physicians and Surgeons-Pakistan* 2014; **24**:676-684.
- Veldhuis-Vlug AG, Tanck MW, Limonard EJ, *et al.* The effects of beta-2 adrenergic agonist and antagonist on human bone metabolism: a randomized controlled trial. *Bone* 2015 Feb; **71**:196-200.
- Weik U, Herforth A, Kolb-Bachofen V and Deinzer R. Acute stress induces proinflammatory signaling at chronic inflammation sites. *Psychosomatic Medicine*. 2008; **70**:906-912.
- Wucherpfennig AL, Chiego DJ Jr and Avery JK. Tritiated thymidine autoradiographic study on the influence of sensory and sympathetic innervation on periodontal wound healing in the rat. *Archives of Oral Biology* 1990; **35**:443-448.
- Yang EV, Bane CM, MacCallum RC, Kiecolt-Glaser JK, Malarkey WB and Glaser R. Stress-related modulation of matrix metalloproteinase expression. *Journal of Neuroimmunology* 2002; **133**:144-150.
- Zeman R, Hirschman A, Hirschman M, Guo G and Etlinger J. Clenbuterol, a beta 2-receptor agonist, reduces net bone loss in denervated hindlimbs. *American Journal of Physiology* 1991; **261**:E285-289.