

Clinical and Radiographic Evaluation of the Periodontium with Biologic Width Invasion by Overextending Restoration Margins - A Pilot Study

Dhelfeson Willya Douglas de Oliveira¹, Marina Natássia Pacheco Maravilha², Thaís Nascimento dos Anjos², Patrícia Furtado Gonçalves³, Olga Dumont Flecha³ and Prof. Karine Tavano³

¹Post-Graduate Program in Dentistry, Federal University of Minas Gerais, Belo Horizonte - MG, Brazil; ²Private Practice, Minas Gerais, Brazil; ³Department of Dentistry, Federal University of Jequití and Mucuri Valleys, Diamantina - MG, Brazil

Abstract

Aim: The aim of this study was to correlate radiographic examination with the clinical periodontal condition in cases of biologic width invasion by overextending restoration margins in restored premolars and molars.

Materials and methods: The present pilot study involved nine people (mean age 32 years) with biologic width invasion by 21 surfaces overextending restoration margins in restored premolars and molars. Radiographs were made in a standardized unit using the interproximal technique and were evaluated by a single calibrated investigator. The clinical periodontal parameters were analyzed with the use of a computerized periodontal probe. Exploratory analysis and Spearman's correlation were used to perform statistical analyses (SPSS, $p < 0.05$).

Results: The most prevalent teeth with biologic width invasion were second premolars and first molars. Mean plaque index was 30.76%, and bleeding on probing was 27.0%. The mesial surface was invaded in 47.6% of cases and the distal surface in 52.4%. The 21 sites with biologic width invasion were found in patients with the following periodontal status: periodontal health (11 sites), gingivitis (2 sites), mild periodontitis (7 sites) and moderate periodontitis (1 site). There was a correlation between plaque index and bleeding on probing with the horizontal component of the bone level.

Conclusions: There was correlation between the radiographic parameters of biologic width invasion and clinical conditions. The measure of the bone crest level correlated with the gingival recession. The horizontal component of bone defect correlated with plaque index and bleeding on probing.

Key words: *Biologic width invasion, radiography, pilot study*

Introduction

The periodontal biologic width is defined as the dimension of the soft tissue that is attached to the portion of the tooth coronal to the crest of the alveolar bone (Tomar

et al., 2013; Rosenberg *et al.*, 1999). The dimension of biologic width is not constant; it depends on the location of the tooth in the alveolus, varies from tooth to tooth and from surface to surface of a specific tooth. A clinically average dimension is 3 mm from the alveolar bone crest up to the cemento-enamel junction (CEJ) in healthy conditions, or up to the margins of the restoration in restored teeth. The average sulcal depth is 0.69 mm, the average length of epithelial attachment is 0.97 mm, and the average length of connective tissue attachment is 1.07 mm (Khuller and Sharma, 2009; Gargiulo *et al.*, 1961).

Correspondence to: Dhelfeson Willya Douglas de Oliveira, Federal University of Minas Gerais, Av. Antonio Carlos, 6.627, Pampulha, Belo Horizonte, Minas Gerais, Brazil, CEP 31270901; Phone/Fax: +55 31 3409-2470, E-mail: dhodont@hotmail.com

These distances allow the appropriate biologic width even when the restoration margins are placed 0.5 mm within the gingival sulcus (Nugala *et al.*, 2012; Oh, 2010).

The existence of the biologic width is fundamental to the insertion of the junctional epithelium and the connective tissue fibers to teeth, and these periodontal structures should be respected during restorative procedures in order to preserve periodontal health (Jorgic-Srdjak *et al.*, 2000; Makigusa, 2009). The placement of a restoration margin seems to be of importance for periodontal health (Amiri-Jezeh *et al.*, 2006). In addition to the influence of several risk factors, the position of the restoration margin may affect the initiation and progression of periodontal diseases (Kosyfaki *et al.*, 2010).

When the restoration margin levels are being evaluated with a periodontal probe and the patient feels discomfort in the gingiva close to a restoration, it may be suggestive that the margin extends into the attachment and that a biologic width invasion has occurred (Galgali and Gontiya, 2011). The signs of invasion of the biologic width are chronic progressive gingival inflammation around the restoration, bleeding on probing, localized gingival hyperplasia, gingival recession, pocket formation, gingivitis and clinical attachment loss (Felippe *et al.*, 2003). Gingival recession is more often found in thin periodontium and periodontal pockets are commonly formed in thicker periodontium (Felippe *et al.*, 2003).

Interproximal radiographic examination can identify interproximal biologic width invasion, and bitewing radiographies are considered the ideal technique for a more accurate assessment (Shobha *et al.*, 2010). Biologic width violations can be corrected by either surgically removing bone proximal to the restoration margin or orthodontically extruding the tooth and thus moving the margin away from the bone (Felippe *et al.*, 2003; Khuller and Sharma, 2009). In such cases, the clinical crown increases and the biologic width is re-established. Then, biological dimensions for connective tissue attachment, epithelial attachment and gingival sulcus are properly sized and arranged around the tooth in order to physiologically keep the supracrestal distance [average 3 mm (Robbins, 2007; Pontoriero and Carnevale, 2001)].

The suggested physiological function of the biologic width is that of a protective barrier for the subjacent periodontal ligament and the supporting alveolar bone from the attack of a pathogenic biofilm present in the oral cavity (Bosshardt and Lang, 2005). Evidence from a recent review suggests that a breach of the biologic width may have an impact on periodontal health by affecting the homeostasis of the periodontal tissues (Schmidt *et al.*, 2013).

However, several views and/or data exist concerning the ideal dimensions of the biologic width, leading to difficulties with respect to the development of clinical recommendations (Schmidt *et al.*, 2013). The

aim of this study was to correlate the radiographic examination with the clinical periodontal condition in cases of periodontium with biologic width invasion by overextending restoration margins in restored premolars and molars.

Materials and methods

This study was approved by the Research Ethics Committee of the Federal University of Jequitinhonha and Mucuri Valleys (UFVJM; protocol #026/12). The study was conducted in accordance with the Declaration of Helsinki, 1975, revised in 2013.

The participants were diagnosed as periodontally healthy or not in accordance with the American Academy of Periodontology classification system for periodontal diseases and conditions (Armitage, 1999). They were informed about the purpose of the study, as well as benefits and risks of participating in the research. Afterward, they received and signed an informed consent form.

The inclusion criteria of this study were patients aged 18 years or more, in good general health, presenting restored posterior teeth with biologic width invasion in the mesial or distal surface, diagnosed clinically and radiographically. According to this criteria, 21 cases with biologic width invasion were selected. The participants were of both genders, with dental records in the UFVJM dental clinic.

Interproximal x-rays were used for the radiographic analysis. The radiographs were made in a single appliance with a standardized time of 0.63 ms by the technique of parallelism and with the use of a holder aid. All patients were dressed according to the standard of biosecurity. The film processing was performed with the time/temperature method (Lannucci and Jansen, 2011). This procedure was carried out by one trained researcher (TNA). The x-rays were assessed by another properly calibrated single researcher (MNPM). To improve image-viewing conditions, black masking was used in order to act as an overlay on the areas outside of the collimated exposure field.

Before the study began, the investigator (MNPM) in charge of radiographic assessments was trained and calibrated for intraexaminer repeatability. The examiner measured a set of randomly chosen radiographic sites twice, with an interval of 7 days between the measurements. The intraclass correlation coefficient was 0.98.

Because there is no consensus in the literature for biologic width invasion determination, the diagnostic method of this condition was based on a systematic review (Schmidt *et al.*, 2013). Briefly, the attachment level was measured by periodontal probing, and the evaluation of the restoration margin and alveolar bone level was made by X-rays. The cut-point to determine biologic width invasion was a distance ≤ 3 mm between the bone crest and the restoration margin (Figure 1).

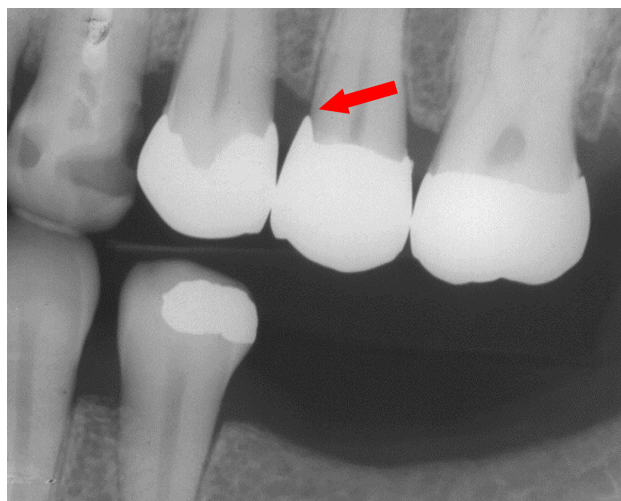

Figure 1. Interproximal radiography of biologic width invasion by overextending margin restoration.

The clinical parameters analyzed were:

1. plaque index (PI; Loe, 1967)
2. bleeding on probing (BP; Mühlemann and Son, 1972)
3. probing depth (PD), determined by the distance from the gingival margin to the base of the gingival sulcus clinically detectable and measured with a computerized periodontal probe (Florida Probe®, Gainesville, FL, USA)
4. height of the gingival recession (HGR), which is the distance from the CEJ to the apical extension of the gingival margin. In cases of biologic width invasion, the more apical extension of the restoration was used as a reference
5. clinical attachment level (CAL), given by the sum of the PD with the HRG;
6. width of the gingival recession (WGR), given by the distance between the mesial and distal gingival margins of the tooth with gingival recession (on a horizontal line tangential to the CEJ)
7. keratinized tissue height (KTH), which is the distance from the gingival margin to the mucogingival line
8. keratinized tissue thickness (KTT), measured using a digital endodontic spreader (Dentsply, Rio de Janeiro, RJ, Brazil) perpendicular to a midpoint between the gingival margin and mucogingival junction and through the soft tissue with light pressure until a hard surface was felt.

The HGR, WGR, KTH and KTT were determined with manual probes and measured in millimeters on the buccal surface. The PI and BP parameters were analyzed throughout the oral cavity and were measured with a computerized periodontal probe at six gingival sites: mesio-buccal, mid-buccal, disto-buccal, mesio-lingual, mid-lingual, and disto-lingual. The other variables were collected only in regions that had invasion of the biologic width.

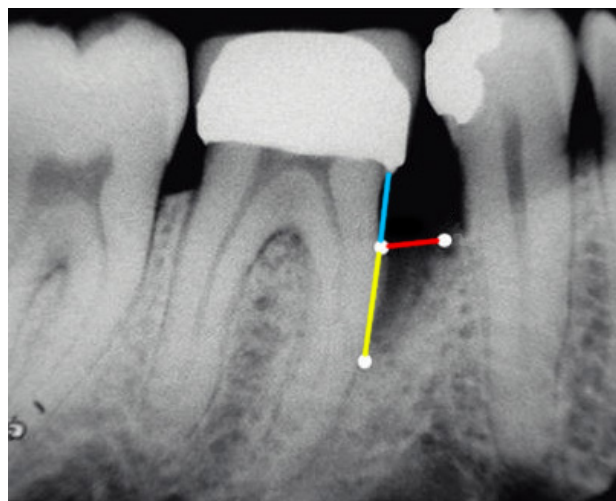


Figure 2 (Adapted from Parashis et al., 2012). Radiographic parameters evaluated: intrabony component (yellow line), bone crest level (blue line), bone defect level (yellow + blue lines), horizontal component (red line).

In cases of intrabony defects, the following radiographic parameters were evaluated (Parashis *et al.*, 2012):

1. bone defect level (BDL), vertical distance from the CEJ to the base of the bone defect at which the periodontal ligament space appeared normal (Figure 2, yellow + blue lines)
2. bone crest level (BCL), vertical distance between the CEJ and the bone crest (Figure 2, blue line)
3. intrabony component (INTRA), defined by subtracting BDL-BCL, *i.e.*, the vertical distance from the bone crest to the base of the defect (Figure 2, yellow line)
4. horizontal component (HC), horizontal distance from the bone crest to the root surface in a perpendicular line to the axis of the tooth with biologic width invasion (Figure 2, red line).

As the present study used teeth with overextending restorations, the more apical extension of the restoration was used as a reference instead the CEJ. These measures were taken with a drypoint compass and measured in millimeters with the aid of a caliper to two decimal places, for greater precision and reliability. These measures (Figure 2, adapted from Parashis *et al.*, 2012) were obtained by a single researcher (MNPM), properly calibrated and trained.

The statistical analyses were conducted using the statistical package SPSS® (Statistical Package for the Social Sciences Inc, IBM, Armonk, NY, USA) version 22.0. Exploratory analysis of the data provided frequencies, averages and standard deviations. The 95% confidence interval and 5% significance level were used. The evaluation of normality of the data was checked by the Shapiro-Wilk test. Spearman's rank correlation coefficient was used to verify the association between clinical and radiographic findings.

Results

The sample consisted of 8 women (88.8%) and 1 man (11.2%), with an average age of 32.10 ± 1.65 years (range 29 to 34 years). The teeth with higher prevalence of biologic width invasion were second premolars and first molars, followed by first premolars, and the teeth with lower prevalence were second molars (*Table 1*). The average plaque index was $30.76 \pm 8.01\%$, and the bleeding on probing was $27.0 \pm 7.0\%$.

In the teeth that showed biologic width invasion, the mesial surface was involved in 47.6% ($n=10$) and the distal surface in 52.4% ($n=11$) of the cases (*Table 1*). The radiographic findings are presented in *Table 2*.

The 21 sites with biologic width invasion were found in patients with the following periodontal status: periodontal health (11 sites), gingivitis (2 sites), mild periodontitis (7 sites) and moderate periodontitis (1 site). Two teeth presented with mobility class I, corresponding to 9.5% of the teeth with biologic width invasion. No teeth with biologic width invasion presented with furcation defects.

The correlation between the clinical and radiographic findings is shown in *Table 3*. There was a significant positive correlation between the plaque index and bleeding on probing with the horizontal component, as well as the height and width of the gingival recession with the bone crest level.

Table 1. Prevalence of biologic width invasion by tooth type and dental surface.

Parameter	Total	
	N	%
Tooth		
First pre-molar	3	14.3
Second pre-molar	8	38.1
First molar	8	38.1
Second molar	2	9.5
Surface		
Mesial	10	47.6
Distal	11	52.4

Table 2. Average of the parameters related to the sites probed ($n = 21$).

Parameters related to the sites probed	Mean \pm SD (mm)
Probing depth	2.23 ± 0.18
Clinical attachment level	2.23 ± 0.18
Height of gingival recession	0.50 ± 0.18
Width of gingival recession	1.38 ± 0.52
Keratinized tissue height	4.85 ± 0.30
Keratinized tissue thickness	1.40 ± 0.16
Level of bone defect	2.81 ± 0.13
Bone crest level	1.98 ± 0.08
Intrabony component	0.83 ± 0.10
Horizontal component	1.05 ± 0.15

Table 3. Spearman rank correlation coefficient (r_s) of clinical and radiographic findings.

Clinical parameters	Radiographic parameters							
	Level of bone defect		Bone crest level		Intrabony component		Horizontal component	
	r_s	p	r_s	p	r_s	p	r_s	p
Tooth	0.289	0.102	-0.078	0.369	0.289	0.102	-0.240	0.148
Site	-0.182	0.215	0.103	0.329	-0.333	0.070	-0.356	0.057
Plaque index	0.150	0.258	-0.065	0.390	0.267	0.121	0.555	0.004*
Bleeding on probing	0.058	0.401	0.005	0.492	0.189	0.206	0.558	0.004*
Probing depth	0.261	0.127	0.096	0.339	0.100	0.333	0.291	0.101
Clinical attachment level	0.217	0.172	0.033	0.444	0.050	0.414	0.259	0.128
Height of gingival recession	0.198	0.195	0.393	0.039*	0.134	0.281	-0.272	0.117
Width of gingival recession	0.134	0.281	0.426	0.027*	0.032	0.445	-0.327	0.074
Keratinized tissue height	0.166	0.237	-0.096	0.339	0.336	0.068	0.176	0.223
Keratinized tissue thickness	0.151	0.257	-0.195	0.198	0.258	0.130	-0.097	0.337
Diagnosis	-0.085	0.357	0.068	0.385	0.103	0.328	0.247	0.140

*Statistically significant correlation

Discussion

In daily practice, overextending margins of dental restorations are a problem frequently observed (Schätzle *et al.*, 2001). Periodontal health is preserved by the correct insertion of the junctional epithelium and the connective tissue fibers to the tooth along the biologic width. There are several studies focused on the relationship between periodontal tissues (clinically assessed) and overhanging prosthetic restorations; however, there is a lack of knowledge about the relationship of clinical periodontal parameters with radiographic findings in biological width invasion in posterior tooth sites. The present research showed a correlation between the radiographic parameters of biologic width invasion and the clinical conditions, mainly the plaque index and bleeding on probing.

When the periodontium is disturbed by clinical procedures and techniques such as cavity fillings, definitive restorations, provisional restorations and dental impressions, tissues can respond with an inflammatory process, eventually followed by apical migration of junctional epithelium and formation of pockets, if other factors favor biofilm formation. Excessive inflammation of the periodontium usually leads to gingival recession in free facial and interproximal surfaces (Sanavi *et al.*, 1998). Gingival recession and inflammation were notably observed in this study. The increase in the width and height components of gingival recession is correlated with increased bone crest level.

Measurements on the buccal surface were performed because all periodontal tissues of the neighboring tooth may also be affected in cases of biologic width invasion in the proximal surfaces (Albandar, 2002; Albandar *et al.*, 1995). The inflammatory process in the mesial/distal surfaces probably spreads throughout surrounding tissues. Thus, signs of periodontal damage, such as gingival inflammation and gingival recession, occur at the free surfaces.

It has been accepted that overextending restorations promote gingivitis by promoting local accumulation of bacterial biofilm rather than resulting in mechanical irritation (Schätzle *et al.*, 2001). In the present study, the high plaque index may be due to the plaque-retaining properties of the rough surface areas brought into the gingival sulcus when indirect restorations were cemented. This condition could potentially lead to more severe gingival inflammation followed by periodontal destruction with increased pocket depth, loss of attachment and gingival recession (Schmidt *et al.*, 2013; Kosyfaki *et al.*, 2010), increasing the vertical bone resorption and then raising the horizontal component. It was not possible to correlate the findings of this study with the literature, as the literature reported studies using anterior teeth (Sadan and Adar, 1998).

Moreover, the placement of slightly overextending restoration margins was shown to result in a change of the subgingival microbiota adjacent to the subgingival restoration, favoring the colonization of Gram-negative, strictly anaerobic rods (Schmidt *et al.*, 2013). It is suggested that the shift of the composition of the subgingival microbiota towards an increased proportion of periodontopathic microorganisms will eventually lead to loss of periodontal support (Schätzle *et al.*, 2001).

Other possible parameters relating to adverse effects of dental restorations on the supportive tissue have also been identified in the literature (Valderhaug *et al.*, 1993), such as the contour (Grosso *et al.*, 1984), the surface roughness of the crown or the cement (Sorensen, 1989), and the time of restoration existence since its insertion (Schätzle *et al.*, 2001). To what extent these factors have influenced the present results is unpredictable.

Many studies describe the importance of radiographic examination for diagnosis of biologic width violation. However, a standard technique for such evaluation has not been established. In this study, the interproximal technique was used because there is less distortion when compared to other techniques, and it allows a greater approximation of reality when probe measurements are compared (Pimentel *et al.*, 2006). The clinical examination of dental restorations should be done in addition to radiographic examination in order to raise the validity of the diagnostic of biologic width invasion.

Studies in this area are important to the establishment of the diagnosis of biologic width invasion when there is a need for restoration procedures in posterior teeth. Some factors are requisites for the success of tooth restorations, including soft tissue integrity and non-violation of the biologic width. Therefore, an understanding of the anatomy and physiology of gingival tissue regarding the teeth and margins of restorations is necessary to achieve satisfactory mastication, aesthetics, and a healthy interface between the restoration and the surrounding soft tissues (Sanavi *et al.*, 1998; Sadan and Adar, 1998).

The present results show that gingival inflammation and bone crest resorption are common findings in cases of restored posterior teeth with biologic width invasion. Considering the natural history and etiopathogenesis of periodontal disease (Tatakis and Kumar, 2005), it might suggest that in cases of posterior restored teeth the presence of intense bleeding and plaque accumulation lead to bone resorption and may cause interproximal bone defects. The present study has corroborated the long-held concept that restorations placed below the gingival margin are detrimental to gingival health (Schätzle *et al.*, 2001). Clinicians should pay attention in these clinical conditions in order to prevent the evolution of bone loss.

Clinical observations show that the gingiva supporting prosthodontically treated teeth often are inflamed and that pocket formation and recession of gingiva may occur (Valderhaug *et al.*, 1993). These characteristics are also observed in periodontitis and gingivitis, and a differential diagnosis has to be done. In cases of periodontium with biologic width invasion, the clinical signs of periodontal reaction are more restricted to the restored tooth. Moreover, bitewing radiographs should be taken in order to evaluate the restoration margins and the bone crest level. The combination of both clinical and radiographic exams is suitable to diagnose biological width invasion. It is important to note that biologic width invasion is closely associated with local periodontal disease and should be classified as acquired deformities and conditions (Armitage, 1999).

The clinical signs observed in the periodontium with biologic width invasion are also frequent in patients with gingivitis and periodontitis. In this study, patients presented with different periodontal health conditions, and this may be one of the limitations of the study. The importance of including only patients who have an exclusive diagnosis of general periodontal health in future studies was noted. Similarly, the absence of a control group may be considered another limitation of the present study, as a control group gives reliable data with which to compare results.

Clinical studies with a greater sample size are needed to corroborate or refute the findings of this study. Also suggested are new longitudinal studies to investigate more relevant periodontal correlations, and the use of regression analysis in order to determine the behavior and causality between the variables.

Conclusions

It was concluded that the distance from the more apical extension of the restoration to the bone crest positively correlated with the height and width of the gingival recession. The horizontal component of bone defect positively correlated with the plaque index and bleeding on probing. Thus, there was a positive correlation between the radiographic parameters of biologic width invasion and the clinical conditions.

Clinicians should use interproximal radiography and clinical evaluation to diagnose cases of biologic width invasion. The presence of bone resorption associated with plaque accumulation, bleeding on probing and gingival recession in restored posterior teeth with over-extending restorations may be considered as biologic width invasion.

Acknowledgments

The authors declare no conflict of interest. The study was supported by the researchers.

References

- Amiri-Jezeh M, Rateitschak E, Weiger R and Walter C. The impact of the margin of restorations on periodontal health - a review. *Schweizer Monatsschrift für Zahnmedizin* 2006; **116**:606-613.
- Armitage GC. Development of a classification system for periodontal diseases and conditions. *Annals of Periodontology* 1999; **4**:1-6.
- Bosshardt DD and Lang NP. The junctional epithelium: from health to disease. *Journal of Dental Research* 2005; **84**:9-20.
- Felippe LA, Monteiro Júnior S, Vieira LC and Araujo E. Reestablishing biologic width with forced eruption. *Quintessence International* 2003; **34**:733-738.
- Galgali SR and Gontiya G. Evaluation of an innovative radiographic technique--parallel profile radiography--to determine the dimensions of dentogingival unit. *Indian Journal of Dental Research* 2011; **22**:237-241.
- Gargiulo A, Wentz F and Orban B. Dimensions and relations of the dentogingival junction in humans. *Journal of Periodontology* 1961; **32**:261-267.
- Grosso JE, Nalbandian J, Sanford C and Bailit H. Effect of restoration quality on periodontal health. *The Journal of Prosthetic Dentistry* 1984; **53**:14-19.
- Jorgic-Srdjak K, Dragoo MR, Bosnjak A, Plancak D, Filipovic I and Lazic D. Periodontal and prosthetic aspect of biological width part II: Reconstruction of anatomy and function. *Acta Stomatologica Croatica* 2000; **34**:441-444.
- Khuller N and Sharma N. Biologic width: Evaluation and correction of its violation. *Journal of Oral Health & Community Dentistry* 2009; **3**:20-25.
- Kosyfaki P, del Pilar Pinilla Martín M and Strub JR. Relationship between crowns and the periodontium: a literature update. *Quintessence International* 2010; **41**:109-126.
- Lannucci JM and Howerton LJ. *Dental Radiography: Principles and Techniques*, 4th ed. Missouri: Elsevier Saunders, 2011.
- Löe H. The gingival index, the plaque index and the retention index systems. *Journal of Periodontology* 1967; **38**:610-616.
- Makigusa K. Histologic comparison of biologic width around teeth versus implant: The effect on bone preservation. *Journal of Implant and Reconstructive Dentistry* 2009; **1**:20-24.
- Mühlemann HR and Son S. Gingival sulcus bleeding a leading symptom in initial gingivitis. *Helvetica Odontologica Acta* 1971; **15**:107-113.
- Nugala B and Kumar SB, Sahitya S, and Krishna PM. Biologic width and its importance in periodontal and restorative dentistry. *Journal of Conservative Dentistry* 2012; **1**:12-17.
- Oh SL. Biologic width and crown lengthening: case reports and review. *General Dentistry* 2010; **5**:200-205.

- Parashis AO, Polychronopoulou A, Tsiklakis K and Tatakis DN. Enamel matrix derivative in intrabony defects. Prognostic parameters of clinical and radiographic treatment outcomes. *Journal of Periodontology* 2012; **83**:1346-1352.
- Pimentel JO, Filho AMM, Mota OML, Pereira SLS, Lima DLF and Carlos MX. [Comparative study between radiographic and surgical evaluation in the diagnosis of invasion of periodontal biological space]. *Revista de Periodontia* 2006; **1**:11-15. (Portuguese)
- Pontoriero R and Carnevale G. Surgical crown lengthening: A 12-month clinical wound healing study. *Journal of Periodontology* 2001; **72**:841-848.
- Robbins JW. Tissue management in restorative dentistry. *Functional Esthetics & Restorative Dentistry* 2007; **1**:40-43.
- Rosenberg ES, Cho SC and Garber DA. Crown lengthening revisited. *Compendium of Continuing Education in Dentistry* 1999; **20**:527.
- Sadan A and Adar P. Esthetic proportions versus biologic width considerations: A clinical dilemma. *Journal of Esthetic Dentistry* 1998; **4**:175-181.
- Sanavi F, Weisgold AS and Rose LF. Biologic width and its relation to periodontal biotypes. *Journal of Esthetic Dentistry* 1998; **3**:157-163.
- Schätzle M, Land NP, Anerud A, Boysen H, Bürgin W and Löe H. The influence of margins of restorations of the periodontal tissues over 26 years. *Journal of Clinical Periodontology* 2001; **28**:57-64.
- Schmidt JC, Sahrman P, Weiger R, Schmidlin PR and Walter C. Biologic width dimensions - a systematic review. *Journal of Clinical Periodontology* 2013; **40**:493-504.
- Serensen JA. A rationale for comparison of plaque-retaining properties of crown systems. *The Journal of Prosthetic Dentistry* 1989; **62**:264-269.
- Shobha KS, Mahantesha, Seshan H, Mani R and Kranti K. Clinical evaluation of the biologic width following surgical crown lengthening procedure: A prospective study. *Journal of Indian Society of Periodontology* 2010; **14**:160-167.
- Tatakis DN and Kumar PS. Etiology and pathogenesis of periodontal diseases. *Dental Clinics of North America* 2005; **49**:491-516.
- Tomar N, Bansal T, Bhandari M and Sharma A. The perio-esthetic-restorative approach for anterior rehabilitation. *Journal of Indian Society of Periodontology* 2013; **4**:535-538.
- Valderhaug J, Ellingsen JE and Jokstad A. Oral hygiene, periodontal conditions and carious lesions in patients treated with dental bridges. A 15-year clinical and radiographic follow-up study. *Journal of Clinical Periodontology* 1993; **20**:482-489.