

Full Mouth Implant-supported Rehabilitation of a Patient with Ectodermal Dysplasia: Clinical Report and Literature Review

Ahmad Kutkut¹, Rasha Abu-Eid², Lina Sharab¹, Behruz Abadi¹
and Joseph Van Sickels³

¹ Department of Oral Health Practice, Division of Restorative Dentistry, College of Dentistry, University of Kentucky, Lexington, KY, USA

² Georgia Regents University Cancer Center, Augusta, Georgia, USA

³ Department of Oral Science, Division of Oral and Maxillofacial Surgery and Hospital Dentistry, University of Kentucky, Lexington, KY, USA

Abstract

Objective: The purpose of this case report is to present the clinical course of full mouth rehabilitation in an 18-year-old female patient with ectodermal dysplasia who was treated with implant-supported fixed partial dentures for the mandible and the maxilla.

Case report: Fourteen dental implants (8 in the maxilla and 6 in the mandible) were placed simultaneously after full mouth extraction and alveoloplasty surgery. After 6 months of healing, prosthetic rehabilitation was started for screw-retained fixed partial dentures. The patient was followed for one year and a peri-implant maintenance regime established for six-month recalls. The patient was satisfied with the prosthesis both esthetically and functionally. Furthermore, the patient reported significant improvements in oral function and psychosocial activities.

Conclusion: The use of dental implants to support full mouth prosthetic rehabilitation for adolescents with ectodermal dysplasia may provide a considerable improvement in function and esthetic compared to conventional removable prosthetic options. This has the potential to enhance the quality of life for these patients.

Key words: Dental implant, prosthetic rehabilitation, ectodermal dysplasia, screw retained, fixed partial denture

Introduction

Ectodermal dysplasia (ED) is a group of hereditary conditions characterized by anomalies in structures of ectodermal origin such as glands, teeth, skin, hair follicles, and nails (National Foundation for Ectodermal Dysplasia, 2014; Nyhan, 1987). There is a wide range of clinical presentations and many criteria have been proposed for classification. The presence or absence of sweat glands is one of the criteria that classify ED into hydrotic and hypohydrotic variants, respectively (Berg *et al.*, 1990).

Hypohydrotic ED is an X-linked disorder; hence, males are affected more severely than females, and among the array of ED conditions, hypohydrotic ED presents with the most severe dental anomalies (Berg *et al.*, 1990). The prevalence of hypohydrotic ED is estimated at one in 5,000–10,000 newborns (National Foundation for Ectodermal Dysplasia, 2014).

Patients with ED might be affected by partial or complete anodontia. Impacted teeth are common and teeth that do erupt are delayed in eruption and usually malformed. Characteristically, teeth are small with a defective morphology, and may be pointed, conical or peg-shaped (National Foundation for Ectodermal dysplasia, 2014; Nyhan, 1987). Under-developed alveolar ridges (Patel, 2002; Raducanu *et al.*, 2010; Yenisey *et al.*, 2004), resulting in the loss of occlusal vertical dimension (OVD) (Bayat *et al.*, 2011; Bulut *et al.*, 2010; Nal-

Correspondence to: Dr. Ahmad Kutkut, Department of Oral Health Practice, Division of Restorative Dentistry, University of Kentucky, College of Dentistry, 800 Rose St., D646, Lexington, KY, USA 40536, Telephone: +1 859-323-4104, Fax: +1 859-257-1847, E-mail: ahmad.kutkut@uky.edu

lanchakrava, 2013; Patel, 2002; Rad *et al.*, 2007; Raducanu *et al.*, 2010), and protuberant lips (Bulut *et al.*, 2010; Nallanchakrava, 2013; Nyhan, 1987; Rad *et al.*, 2007), are among the ED oral manifestations that influence dental treatment. ED patients have a characteristic facial appearance with frontal bossing, prominent supraorbital ridges, underdeveloped maxillae and a depressed saddle-like nose (Bulut *et al.*, 2010; Nallanchakrava, 2013; Nyhan, 1987; Rad *et al.*, 2007; Raducanu *et al.*, 2010). Hypohydrotic ED is usually transmitted as an X-linked recessive trait in which the gene is carried by the female and manifested in the male. In about 70% of cases, carriers of hydrotic ED experience some features of the condition. The carrier female has a 50% chance of transmitting the disorder to her children. Mutation in the EDA gene is known to be associated with X-linked HED. Other genes, EDAR and EDARADD, are known to be associated with the autosomal dominant and autosomal recessive forms of the condition (Deshmukh and Prashanth, 2012).

Males are usually affected more than females in X-linked HED. However, the alveolar ridge is usually affected by underdevelopment due to missing teeth. An X-linked HED defective gene was cloned, leading to the identification of a novel signaling molecule of the tumor necrosis factor (TNF) named ectodysplasin (EDA) (Kere *et al.*, 1996; Ezer *et al.*, 1997).

Hypohydrotic ED is not associated with a syndrome known to affect the ectodermal derivatives. Therefore, the effect on bone quality is not yet clear. However, it was found that mutations in the ligand, receptor, or the receptor-associated protein may cause XL-HED, AR-HED, or AD-HED. Mutations in the components further downstream of the pathway may also cause HED in association with immunodeficiency (ID) and osteoporosis and lymphoedema (OL; Courtois and Smahi, 2006).

The role of EDA during placode formation has been tested in HED mouse models. The role of NF- κ B downstream of Edar has been confirmed by the discovery of the first transcriptional target genes. Downstream targets of EDA are clear candidates in search for novel genes behind ectodermal dysplasia (Mikkola, 2009). More recently, a rat model was successfully produced to study HED (Kuramoto *et al.*, 2011). More research is needed to assist in defining clear etiology, pathological role and effect of HED.

In addition to the functional problems associated with hypodontia, ED patients are also concerned about their aesthetic appearance, leading to social anxiety (Armellini *et al.*, 2005; Nallanchakrava, 2013; Rad *et al.*, 2007). Therefore, it is important to provide comprehensive dental care for these patients at an early age to ensure normal physiological and psychological growth and development.

Traditionally, prosthodontic treatment is used to treat hypodontia associated with ED. Patients are fitted with fixed and removable prostheses, partial or complete dentures or over-dentures. Removable prostheses are typically used in children and adolescent patients and are continually replaced to accommodate skeletal growth (Bhargava *et al.*, 2010; Gupta and Tyagi, 2011; Ladda *et al.*, 2013; Nallanchakrava, 2013; Patel, 2002; Pigno *et al.*, 1996; Yenisey *et al.*, 2004). However, addressing all the dental and oral problems associated with ED requires a multidisciplinary team for the full rehabilitation of ED patients who might require periodontal, restorative, endodontic, prosthodontic, orthodontic and surgical treatments (Bayat *et al.*, 2011; Dhima *et al.*, 2014; Patel, 2002; Van Sickels *et al.*, 2010; Yenisey *et al.*, 2004).

The rapid and continuous development of endosseous implants over the last few decades has provided a new optimal treatment of ED-associated hypodontia, and several reports have demonstrated successful full mouth rehabilitation using dental implants (Bayat *et al.*, 2011; Guckes *et al.*, 2002; Rad *et al.*, 2007). High success rates and survival of implants have been reported in ED patients (Guckes *et al.*, 2002; Sweeney *et al.*, 2005; Yap and Klineberg, 2009). Guckes *et al.* (2002) reported the survival of 91% of mandibular and 76% of maxillary implants in patients with ED. Although there is a higher number of complications associated with dental implants in ED patients, over 91% who received this treatment are satisfied with the outcome (Stanford *et al.*, 2008).

Dental implants are not the usual treatment for children and adolescents with anodontia. This is mainly because implants do not follow the growth of the jaw and therefore become similar to ankylosed teeth (Op Heij *et al.*, 2003; Rossi and Andreasen, 2003). Furthermore, the insertion of implants at a young age can disrupt the development and eruption of adjacent tooth germs in addition to affecting the growth of the alveolar bone (Rossi and Andreasen, 2003). Despite these difficulties, it has been shown that implant failure in adolescent patients is only slightly higher than in adult patients (Bergendal *et al.*, 2008). In fact, no significant differences in implant survival in ED patients based on patient age have been reported (Guckes *et al.*, 2002). However, in their study, Bergendal *et al.* (2008) reported that among adolescents treated with implants, adolescents with anodontia related to ED have a higher failure rate. The authors attributed that to the underdeveloped jaws and the poor pre-operative conditions - mainly the bone quality and quantity (Bergendal *et al.*, 2008). Nevertheless, several reports have demonstrated successful treatment of adolescents with ED-related anodontia using osseointegrated implants (Bergendal *et al.*, 1991; Bulut *et al.*, 2010; Guckes *et al.*, 1997; Kearns *et al.*, 1999; Kramer *et al.*, 2007). Kearns *et al.* (1999) reported a 97% successful integration rate for adolescent ED patients.

Several approaches have been employed to overcome the difficulties associated with placing implants in ED patients. For instance, the problem of submerged implants upon tissue growth can be addressed by the use of longer abutments and revision of the prosthesis (Kearns *et al.*, 1999). Bone grafting maybe a solution if the lack of alveolar bone development presents a problem for placing implants (Bayat *et al.*, 2011), and orthognathic surgery can be performed to reposition the jaws, thus enabling a functional placement of implant-retained prostheses (Bayat *et al.*, 2011; Dhima *et al.*, 2014; Van Sickels *et al.*, 2010). The replacement of teeth because of ED in young patients can be an important indication for early implant therapy. Osseointegrated dental implants such as ankylosed teeth or implant-supported prostheses may be reported with a lack of proper occlusion as a result of alteration to the position due to growth-related changes that occur within the dental arch. It is evident that growth of the adolescent creates a significant risk of discrepancy in esthetic and/or functional outcome. For those patients, the placement of a dental implant should be delayed until complete growth has occurred (Heij *et al.*, 2006).

This is a case report of an 18-year-old adolescent patient who presented with hydrotic ED and severe hypodontia. A multidisciplinary treatment approach was used for full mouth rehabilitation using implant-supported prosthetics.

Case report

An 18-year-old female patient with hydrotic ectodermal dysplasia was referred for prosthodontic rehabilitation at the University of Kentucky, College of Dentistry. Her chief complaints included a difficulty in function, chewing, and poor esthetics. She signed A HIPAA and consent forms for treatment.

Comprehensive clinical and radiographic examination reported multiple missing teeth, ankylosed worn primary teeth (*Figure 1*), permanent central incisors and first molars in the upper arch, permanent canines and molars in the lower arch, and deep overbite occlusion with minimal inter-arch space with loss of occlusal

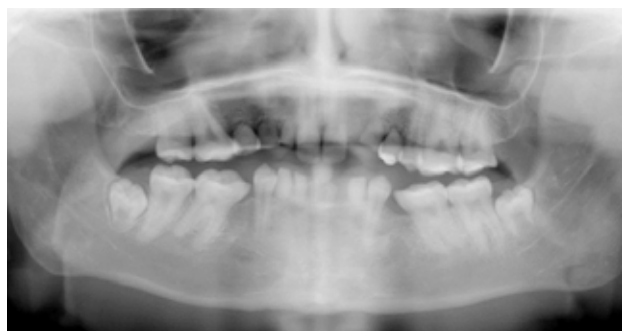

Figure 1. Preoperative panoramic X-ray.

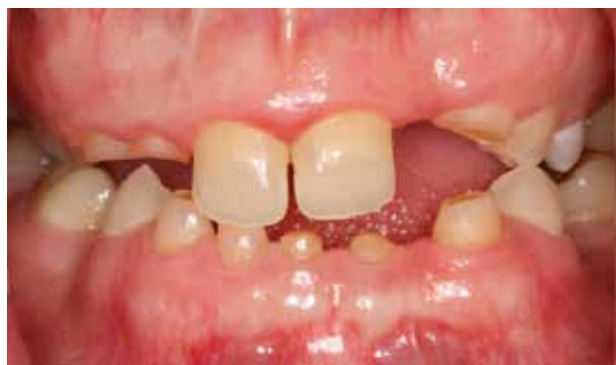

Figure 2. Preoperative clinical picture shows hypodontia, ankylosed retained primary teeth and minimal inter-arch space with loss of occlusal vertical dimension.

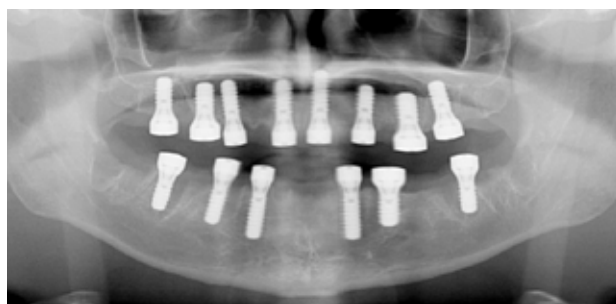

Figure 3. Post-surgical X-ray. All remaining teeth were extracted and 14 implants placed simultaneously with alveoplasty in the maxillary and mandibular ridges.

vertical dimension OVD (*Figure 2*). Consultations were obtained from Orthodontics and Oral and Maxillofacial Surgery Departments. Orthodontic treatment was not indicated, and based on the prosthodontist's and surgeon's consultations, it was agreed that extracting all non-restorable primary teeth, permanent central incisors and molars was indicated, to be replaced with implant-supported fixed restorations. Eleven retained primary teeth were identified with severe wear and submerged relative to the permanent teeth.

A treatment plan with two stages was designed. The first stage included the extraction of the remaining teeth and the placement of 14 implants (Straumann USA® Standard Plus SLA implants) simultaneously with alveoplasty surgery (*Figure 3*). The second stage involved restoring the dentition with implant-supported prostheses, which were completed at 6 months after extraction, alveoplasty, and implant placement surgery.

The surgical procedure was performed under general anesthesia. Fourteen Straumann implants (Straumann ITI Implant System, Straumann USA LLC, Andover, MA) of various heights and widths were placed at sites 3, 5, 6, 8, 9, 11, 13, 14, 18, 20, 22, 27, 29 and 31. Interim maxillary and mandibular overdenture prostheses were fabricated for esthetics and function during the healing time. A diagnostic wax-up was completed and reproduced for fabrication of ceramometal restorations.

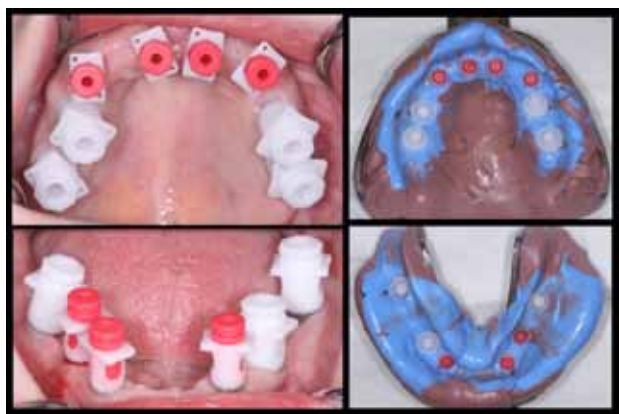


Figure 4. Straumann synOcta® impression copings were used for implant level polyvinyl siloxane (PVS) impressions.

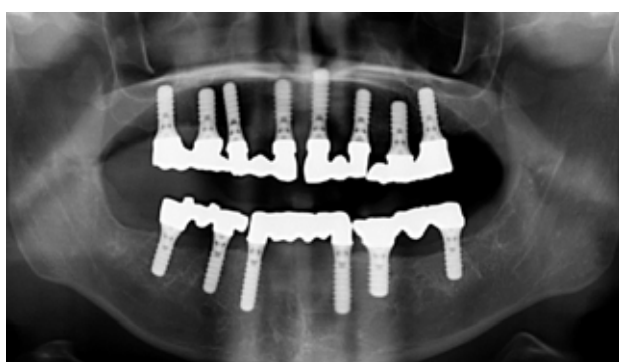

Figure 5. Metal try-in performed for 7 screw-retained fixed partial denture prostheses. Panoramic X-ray six months after implant placement.

Six months after the surgical procedure, clinical and radiographic examinations confirmed the osseointegration of all 14 implants. This observation was reported for patients with ED who received dental implants (Davarpanah *et al.*, 1997; Guckes *et al.*, 1997; Rad *et al.*, 2007). synOcta® impression copings were used for implant level polyvinyl siloxane (PVS) (Monophase, Dentsply, PA) impression material using the closed tray technique for maxillary and mandibular implants (Figure 4). The impressions were poured in type IV die stone (UltiRock, Whip Mix, Louisville, KY). Occlusion was established using record bases and wax rims as for edentulous cases initially. Facebow (Whip Mix Corporation, Louisville, KY) and centric relation were recorded with a vinyl polysiloxane bite registration material (Blu-Mousse® VPS Bite Registration Material, Patterson Dental, Louisville, KY). Casts were mounted on a semiadjustable articulator (Whip Mix Model 2340 Articulator, Whip Mix Corporation, Louisville, KY). Straumann synOcta® 1.5 mm screw-retained abutments were used to fabricate screw-retained fixed partial denture prostheses (FPDP) for ease of retrievability (3-5, 6-8, 9-11, 12-14, 18-21, 22-27, 29-31 FPDP). Clinically, a metal try-in was performed for the screw-retained fixed partial denture prosthesis to ensure passive fitness with metal vertical stops

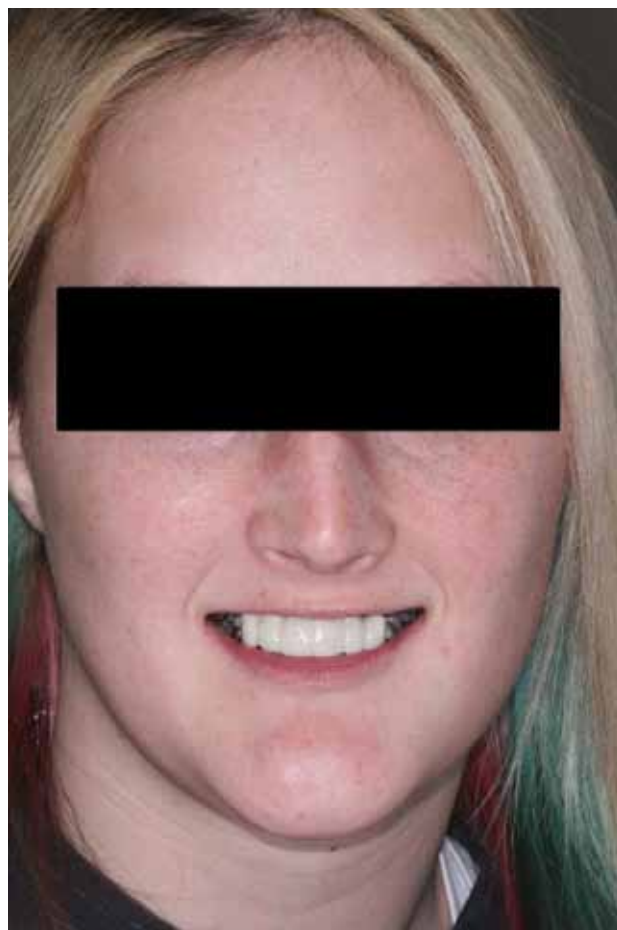

Figure 6. Provisional restorations were used to evaluate anterior esthetics.

and to verify the centric relation. The implant-supported fixed prosthodontic occlusion concept (i.e., mutually protected occlusion; Misch and Bidez, 2005) was applied for this occlusal scheme (Figure 5). Provisional restorations were used to evaluate anterior esthetics; midline, lip line, lip support, and smile line (Figure 6). Ceramo-metal FPDP were completed and a clinical remount was performed to refine the occlusion (Figure 7). Straumann synOcta® abutments were torqued based on manufacturers' recommendations. Screw-retained fixed partial dentures were torqued based on manufacturers' recommendations (Figure 8). Occlusion was checked and adjusted. Screw access holes were filled with cotton pellets and closed with Fermit temporary restorative material (Fermit Resin, Ivoclar Vivadent, Buffalo, NY). Oral hygiene instructions were given to the patient. The patient was instructed to clean between and under the prostheses using Water Pick®, Proxabrushes®, and Supra Floss®. Follow-ups were performed after the first week and first month, and no implants were lost after 1 year of treatment. The patient is under maintenance therapy in the local primary dentist's office. The patient was satisfied with the function and the esthetic outcomes and reported improvements in oral function and self-confidence (Figure 9).

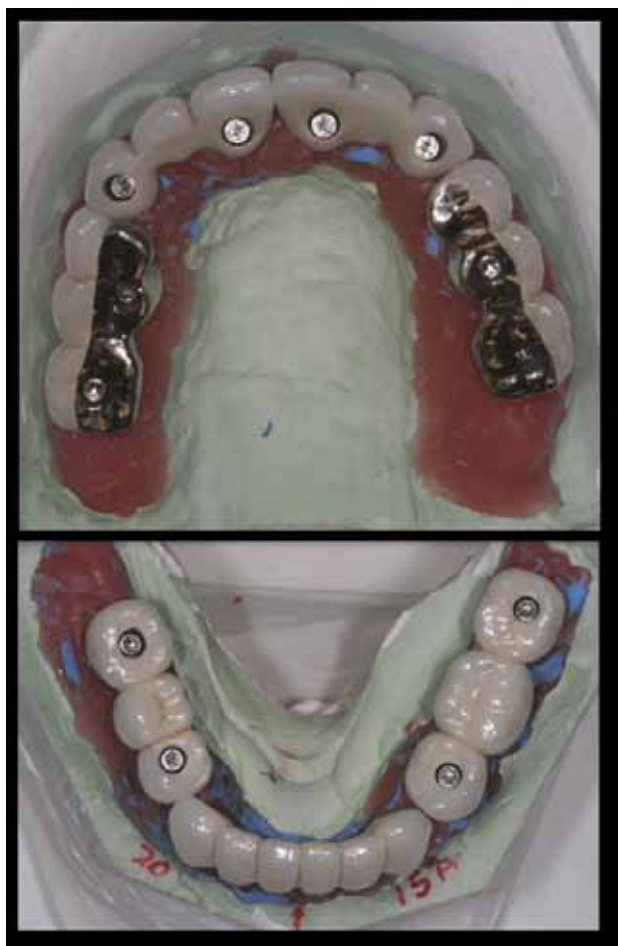


Figure 7. Ceramo-metal restorations completed.

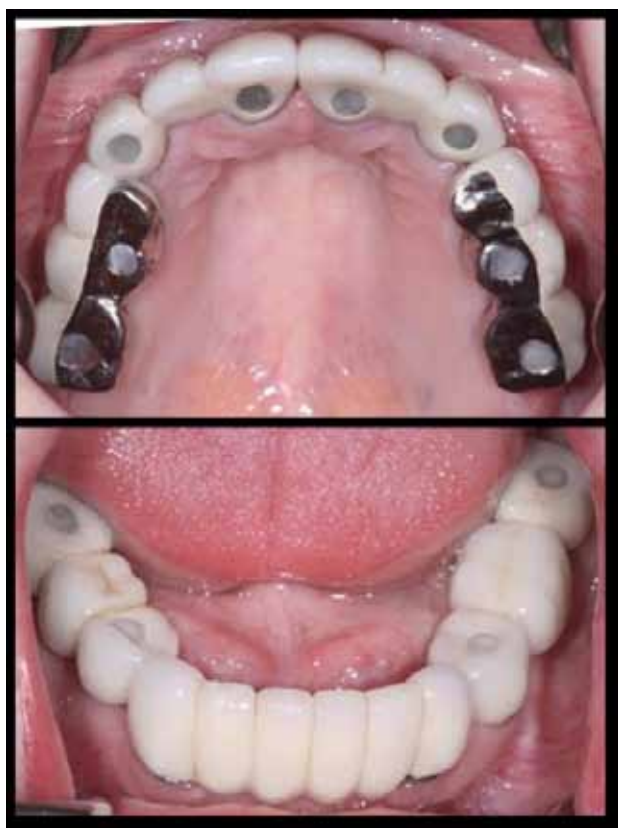

Figure 8. Screw-retained fixed partial dentures were torqued based on the manufacturers' recommendations.

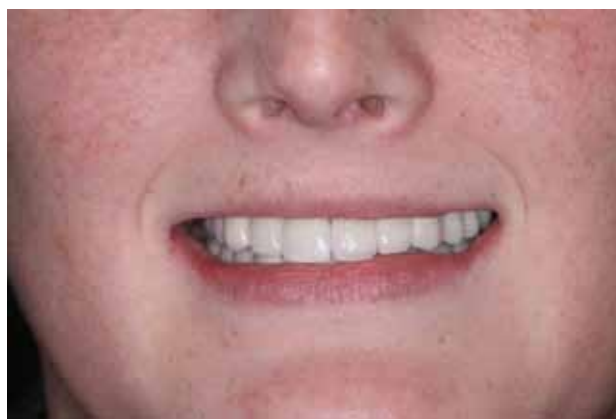

Figure 9. The patient was satisfied with the function and the esthetic outcomes.

Discussion

Ectodermal dysplasia presents a group of patients with severe hereditary anomalies in structures of ectodermal origin such as glands, teeth, skin, hair follicles, and nails (National Foundation for Ectodermal Dysplasia, 2014; Nyhan, 1987). Hypodontia and anodontia are considered the most common oral characteristics of ED (Rad *et al.*, 2007). Osseointegrated implants provide an alternative treatment to conventional removable overdenture prostheses with major improvement in the long-term prognosis for oral rehabilitation (Davarpanah *et al.*, 1997; Guckes *et al.*, 1997; Rad *et al.*, 2007). Although high success rates of implant restorations in patients with ED have been reported, multiple concerns must be taken into consideration when treating these cases. Among these are the maxillomandibular relationship, the remaining deciduous and permanent teeth in each arch and their positions, the volume of the alveolar bone available, and the age of the patient (Bergendal *et al.*, 1991; Bergendal *et al.*, 2008; Guckes *et al.*, 2002; Kearns *et al.*, 1999; Kramer *et al.*, 2007; Sweeney *et al.*, 2005; Van Sickels *et al.*, 2010).

This report describes the full mouth rehabilitation of an ED patient using 14 dental implants to support seven fixed partial denture prostheses in the maxilla and the mandible. The adolescent patient presented in this case report was treated after the completion of growth, when minimal alveolar growth can be anticipated. A multidisciplinary team was consulted, and following the patient's evaluation she was referred for prosthetic rehabilitation. Over the years, the patient had received several removable prostheses, the most frequently reported treatment modality for the dental management of ED (Pigno *et al.*, 1996). At the time of her referral, she was skeletally mature and ready for definitive restorative treatment. Because the ultimate plan for the patient consisted of fixed restorations, the treatment was provided in two stages, surgical and prosthetic rehabilitations.

It has been indicated in the literature that implant-supported prostheses provide a significant improvement in the physiologic and psychosocial function of adolescent patients when compared with their condition before the implants were placed (Guckes *et al.*, 2002; Kent, 1992; Kent and Johns, 1991; Pigno *et al.*, 1996; Stanford *et al.*, 2008; Sweeney *et al.*, 2005; Van Sickels *et al.*, 2010; Yap and Klineberg, 2009). Another factor when considering dental implants in the treatment of ED is the important impact of osseointegrated implants on the preservation of alveolar bone (Denissen *et al.*, 1993; Kalk *et al.*, 1993; Murphy, 1995; van Woweren *et al.*, 1990). Ectodermal dysplasia patients usually present with underdeveloped alveolar ridges because of the lack of tooth development. Underdeveloped alveolar ridges must support a dental prosthesis over the course of a lifetime. Thus, implant treatment will maintain alveolar bone and enhance the prognosis for future prosthodontic treatment (Guckes *et al.*, 2002; Kent, 1992; Kent and Johns, 1991; Pigno *et al.*, 1996; Stanford *et al.*, 2008; Sweeney *et al.*, 2005; Van Sickels *et al.*, 2010; Yap and Klineberg, 2009). Therefore, for this case, implant-supported fixed partial denture prostheses were chosen as the treatment of choice.

Eight osseointegrated implants were placed in the maxillary arch and six osseointegrated implants were placed in the mandibular arch immediately after extraction of all remaining teeth and performance of alveoloplasty. Because of the necessity of using general anesthesia and the fact that further surgeries would be very difficult to carry out in the future, all 14 of the implants were placed during the same surgery. The osseointegration was successful for all 14 implants, and after 1 year of follow-up appointments, there was no loss of any of the implants or the prostheses. Peri-implant maintenance was established for 6-month recalls.

Prosthodontic treatment with seven fixed partial denture prostheses supported by 14 implants improved the patient's esthetic and functional condition and obviously increased her psychosocial confidence and activities. In conclusion, this case report suggests that the use of dental implants in the rehabilitation of ED patients can provide excellent support for dental rehabilitation, both functionally and esthetically.

Conclusion and Summary

Patients with ED present to the dental practitioner with multiple restorative issues. Because of the compromised dental status, these issues also have psychosocial implications. Removable prosthodontics is the most frequent treatment modality used for dental management of ED. Although complete dentures are an acceptable modality of treatment, maintaining natural teeth with overdentures or removable partial dentures is desirable for the preservation of alveolar bone. Implant-supported restorations can maintain alveolar bone and improve functional and psychosocial concerns when compared with removable prostheses. When implant placement in ED patients is considered, their dental and skeletal maturity should be the determining factor. An individual's

growth curve can help in making a decision to use implants as a treatment modality. An integrated multidisciplinary approach can provide superior results. In this case, restorative goals guided the overall treatment plan, requiring the integration of restorative services at several stages of care, which involved prosthodontics and oral and maxillofacial surgery.

Acknowledgments

The authors would like to thank Mr. Robert S. Caskey, CDT for his contribution to the fabrication of the prosthesis. The authors have no conflict of interest.

References

- Armellini D, Carmichael R, Daskalogiannakis J and von Fraunhofer JA. Camouflaging changes in the appearance of a patient with ectodermal dysplasia. *Implant Dentistry* 2005; **14**:227-231.
- Bayat M, Khobyari MM, Dalband M and Momen-Heravi F. Full mouth implant rehabilitation of a patient with ectodermal dysplasia after orthognathic surgery, sinus and ridge augmentation: a clinical report. *Journal of Advanced Prosthodontics* 2011; **3**:96-100.
- Berg D, Weingold DH, Abson K and Olsen EA. Sweating in ectodermal dysplasia syndromes. A review. *Archives of Dermatology* 1990; **126**:1075-1079.
- Bergendal B, Ekman A and Nilsson P. Implant failure in young children with ectodermal dysplasia: a retrospective evaluation of use and outcome of dental implant treatment in children in Sweden. *International Journal of Oral and Maxillofacial Implants* 2008; **23**:520-524.
- Bergendal T, Eckerdal O, Hallonsten AL, Koch G, Kurol J and Kvint S. Osseointegrated implants in the oral habilitation of a boy with ectodermal dysplasia: a case report. *International Dental Journal* 1991; **41**:149-156.
- Bhargava A, Sharma A, Popli S and Bhargava R. Prosthodontic management of a child with ectodermal dysplasia: a case report. *Journal of Indian Prosthodontic Society* 2010; **10**:137-140.
- Bulut E, Guler AU, Sen Tunc E and Telciglu NT. Oral rehabilitation with endosseous implants in a child with ectodermal dysplasia: a case report. *European Journal of Paediatric Dentistry* 2010; **11**:149-152.
- Courtois G and Smahi A. NF-kappaB-related genetic diseases. *Cell Death Differentiation Journal*. 2006; **13**:843-851.
- Davarpanah M, Moon JW, Yang LR, Celletti R and Martínez H. Dental implants in the oral rehabilitation of a teenager with hypohidrotic ectodermal dysplasia: report of a case. *International Journal of Oral and Maxillofacial Implants* 1997; **12**:252-258
- Denissen HW, Kalk W, Veldhuis HA and van Waas MA. Anatomic consideration for preventive implantation. *International Journal of Oral and Maxillofacial Implants* 1993; **8**:191-196.

- Deshmukh S and Prashanth S. Ectodermal dysplasia: A genetic review. *International Journal of Clinical Pediatric Dentistry*, 2012; **5**:197-202.
- Dhima, M., Salinas TJ, Cofer SA and Rieck KL. Rehabilitation of medically complex ectodermal dysplasia with novel surgical and prosthodontic protocols. *International Journal of Oral and Maxillofacial Surgery*, 2014; **43**:301-304.
- Ezer S, Schlessinger D, Srivastava A and Kere J. Anhidrotic ectodermal dysplasia (EDA) protein expressed in MCF-7 cells associates with cell membrane and induces rounding. *Human Molecular Genetics*. 1997; **6**:1581-1587.
- Guckes AD, McCarthy GR and Brahim J. Use of endosseous implants in a 3-year-old child with ectodermal dysplasia: case report and 5-year follow-up. *Pediatric Dentistry* 1997; **19**:282-285.
- Guckes AD, Scurria MS, King TS, McCarthy GR and Brahim JS. Prospective clinical trial of dental implants in persons with ectodermal dysplasia. *Journal of Prosthetic Dentistry* 2002; **88**:21-25.
- Gupta S and Tyagi P. Prosthodontic management of anhidrotic ectodermal dysplasia. *Indian Journal of Dental Research* 2011; **22**:348-351.
- Heij DG, Opdebeeck H, van Steenberghe D, Kokich VG, Belser U and Quirynen M. Facial development, continuous tooth eruption, and mesial drift as compromising factors for implant placement. *International Journal of Oral and Maxillofacial Implants*. 2006; **21**:867-878.
- Kalk W, Denissen HW and Kayser AF. Preventive goals in oral implantology. *International Dental Journal* 1993; **43**:483-491.
- Kearns G, Sharma A, Perrott D, Schmidt B, Kaban L and Vargervik K. Placement of endosseous implants in children and adolescents with hereditary ectodermal dysplasia. *Oral Surgery, Oral Medicine, Oral Pathology, Oral Radiology, and Endodontology* 1999; **88**:5-10.
- Kent G. Effects of osseointegrated implants on psychological and social well-being: a literature review. *Journal of Prosthetic Dentistry* 1992; **68**:515-518.
- Kent G and Johns R. A controlled study on the psychological effects of osseointegrated dental implants. *International Journal of Oral and Maxillofacial Implants* 1991; **6**:470-474.
- Kere J, Srivastava AK, Montonen O, et al. X-linked anhidrotic (hypohidrotic) ectodermal dysplasia is caused by mutation in a novel transmembrane protein. *Nature Genetics*. 1996; **13**:409-416.
- Kramer FJ, Baethge C and Tschernitschek H. Implants in children with ectodermal dysplasia: a case report and literature review. *Clinical Oral Implants Research* 2007; **18**:140-146.
- Kuramoto T, Yokoe M, Hashimoto R, Hiai H and Serikawa T. A rat model of hypohidrotic ectodermal dysplasia carries a missense mutation in the Edaradd gene. *BMC Genetics*. 2011; **21**:12-91.
- Ladda R, Gangadhar S, Kasat V and Bhandari A. Prosthodontic management of hypohidrotic ectodermal dysplasia with anodontia: a case report in pediatric patient and review of literature. *Annals of Medical and Health Sciences Research* 2013; **3**:277-281.
- Mikkola ML. Molecular aspects of hypohidrotic ectodermal dysplasia. *American Journal of Medical Genetics A*. 2009; **149A**:2031-2036.
- Misch CE and Bidez MW. Occlusal considerations for implant-supported prostheses: Implant protected occlusion. *Dental Implant Prosthetics* (ed. 3). Elsevier, Mosby, 2005, 472-510.
- Murphy WM. Clinical and experimental bone changes after intraosseous implantation. *Journal of Prosthetic Dentistry* 1995; **73**:31-35.
- Nallanchakrava S. Oral rehabilitation of a patient with ectodermal dysplasia with prosthodontics treatment. *Indian Journal of Dermatology* 2013; **58**:241.
- National Foundation for Ectodermal Dysplasia 2014; Available from: <http://www.nfed.org/>.
- Nyhan WL. *Diagnostic Recognition of Genetic Disease*. 1 ed. Lea & Febiger, Philadelphia, 1987.
- Op Heij DG, Opdebeeck H, van Steenberghe D and Quirynen M. Age as compromising factor for implant insertion. *Periodontology* 2000 2003; **33**:172-184.
- Patel MI. Prosthodontic rehabilitation of a patient with partial anodontia: a clinical report. *Journal of Prosthetic Dentistry* 2002; **88**:132-134.
- Pigno MA, Blackman RB, Cronin RJ Jr and Cavazos E. Prosthodontic management of ectodermal dysplasia: a review of the literature. *Journal of Prosthetic Dentistry* 1996; **76**:541-545.
- Rad AS, Siadat H, Monzavi A and Mangoli AA. Full mouth rehabilitation of a hypohidrotic ectodermal dysplasia patient with dental implants: a clinical report. *Journal of Prosthodontics* 2007; **16**:209-213.
- Raducanu AM, Pauna M, and Feraru IV. A simple prosthetic restorative solution of a single peg-shaped upper central primary incisor in a case of ectodermal dysplasia. *Romanian Journal of Morphology and Embryology* 2010; **51**:371-374.
- Rossi E and Andreasen JO. Maxillary bone growth and implant positioning in a young patient: a case report. *International Journal of Periodontics and Restorative Dentistry* 2003; **23**:113-119.
- Stanford CM, Guckes A, Fete M, Srun S and Richter MK. Perceptions of outcomes of implant therapy in patients with ectodermal dysplasia syndromes. *International Journal of Prosthodontics* 2008; **21**:195-200.
- Sweeney IP, Ferguson JW, Heggie AA and Lucas JO. Treatment outcomes for adolescent ectodermal dysplasia patients treated with dental implants. *International Journal of Pediatric Dentistry* 2005; **15**:241-248.
- van Sickels JE, Raybould TP and Hicks EP. Interdisciplinary management of patients with ectodermal dysplasia. *Journal of Oral Implantology* 2010; **36**:239-245.

- van Wouern N, Harder F, Hjorting-Hansen E and Gotfredsen K. ITI implants with overdentures: a prevention of bone loss in edentulous mandibles? *International Journal of Oral and Maxillofacial Implants* 1990; **5**:135-139.
- Yap AK and Klineberg I. Dental implants in patients with ectodermal dysplasia and tooth agenesis: a critical review of the literature. *International Journal of Prosthodontics* 2009; **22**:268-276.
- Yenisey M, Guler A and Unal U. Orthodontic and prosthodontic treatment of ectodermal dysplasia--a case report. *British Dental Journal* 2004; **196**:677-679.